

## A rare case of intrauterine lipoma: A masterful masquerade

Varun Bajaj<sup>1</sup>, KC Singh<sup>2,\*</sup>, Rony Chakravarty<sup>3</sup>

<sup>1</sup>Graded Specialist, <sup>2,3</sup>Classified Specialist, Dept. of Pathology, Dept. of Obstetrics and Gynaecology, <sup>1,3</sup>Military Hospital, Wellington, Tamil Nadu, <sup>2,6</sup>Airforce Hospital, Coimbatore, Tamil Nadu, India

**\*Corresponding Author: KC Singh**

Email: malvithain@gmail.com

Received: 12<sup>th</sup> July, 2018

Accepted: 2<sup>nd</sup> August, 2018

### Abstract

**Introduction:** Pure lipomas of the uterus are exceedingly rare, and their origin is of deep interest in terms of histogenesis. The tumours often pose a diagnostic challenge and a host of differentials are made on clinical and radiological assessment. The authors present a case of a pure uterine lipoma detected at a peripheral Airforce hospital.

**Materials and Methods:** Case report with clinical, ultrasound and histopathological findings.

**Conclusion:** A rare case with a controversial histogenesis and recently described chromosomal anomalies adds to our knowledge of this uncharacteristic lesion in the uterine corpus.

**Keywords:** Hamartoma, Leiomyoma, Lipo-leiomyoma.

### Introduction

Uterine Lipomas are exceedingly rare entities with a handful of reported cases worldwide.<sup>1</sup> First described in 1816 by Lobstein, overall incidence of lipomatous tumours in the uterus has been reported to be 0.02-0.03 %.<sup>2,3</sup> The typical clinical profile is an elderly female (50-70 years age) who has attained menopause and presenting with symptoms and signs of a pelvic mass. Histological spectrum of these lesions though variates from a pure lipoma, lipo-leiomyoma to a lipofibroma.<sup>4</sup> Although presence of mature adipocytes in the uterine wall is not uncommon a full blown pure lipomatous lesion seldom shapes up. Largest clinicopathological case series on lipomatous tumours of uterus is of ten cases of which only one was a pure lipoma.<sup>5</sup> Sefarini et al have described the radiological findings of these tumours in a case series of eleven cases.<sup>6</sup> Considered hamartomatous by most authors these lesions can masquerade as more sinister lesions and cause doubt in the mind of the treating surgeon and cause a malignancy scare in the patient.

### Case Report

58 years old post-menopausal lady with comorbidities in the form of Diabetes Mellitus and Hypertension presented to the emergency department of a peripheral Airforce hospital with complaints of pain abdomen and acute retention of urine. On examination her vital parameters were stable, and a mass was palpated in the lower abdomen parallel to the midline corresponding to approximately a 14-16 weeks gravid uterus.

Haematological and Biochemical profile of the patient showed a controlled diabetic state with HbA1c of 6.5%. Imaging of the abdomen revealed a large, homogenous, well defined, hyperechoic mass with partially hypoechoic rim. There was no evidence of internal vascularity within the lesion. Based on the imaging a possibility of a lipo-leiomyoma with hydroureter and hydronephrosis was suggested. (Fig. 1)

A laparotomy to visualise the uterus and subsequent total hysterectomy was decided as the treatment choice in view of bothersome symptoms being experienced, post-menopausal age group being in favour and reproductive desire being non-existent post family completion.

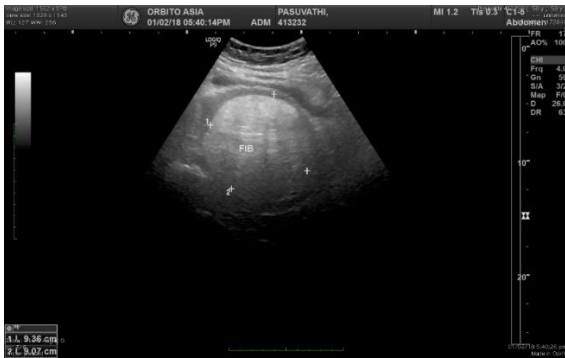Per operatively Uterus corresponding to 16 weeks of gestational size was seen impacted onto the pelvis compressing the ureters and the bladder. Ovaries appeared to be normal.

The uterine specimen was sent to Military Hospital Laboratory for histopathological examination.

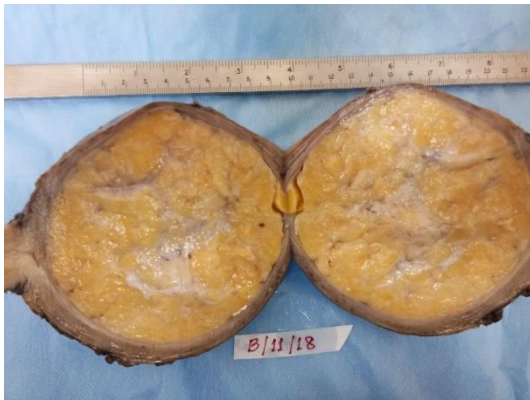
Gross examination of the specimen revealed an enlarged uterus measuring 13 x 11 x 9 cm with a short cervix of 2 cm length. Serosal surface of the uterus was globular and smooth. Cut surface showed a globular mass measuring 9.5 x 9 x 9 cm completely replacing the uterine parenchyma and pushing the myometrium to a 1 cm rim around the mass. Endometrial cavity was not visible. The mass was yellowish in colour, had a firm consistency with no infiltration into surrounding uterine wall on gross. (Fig. 2)

Microscopic examination showed a lobulated tumour composed of mature adipocytes with fine septal vascularity. No lipoblasts were noted. No spindle cell component was appreciated on extensive sectioning. Based on the above findings a diagnosis of Lipoma of the uterus was given. (Fig. 3)

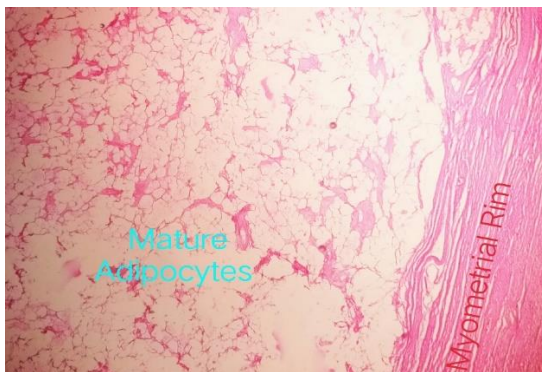
Post operatively the patient's symptoms were alleviated and recovery was uneventful.



**Fig. 1: Ultrasound Image of the uterine mass**



**Fig. 2: Gross appearance of uterine mass**



**Fig. 3**

## Discussion

Fatty tumours of the uterus are exceedingly rare with an overall incidence of 0.03-0.2% with pure lipomas being extremely rare. Presence of fat in a musculo-glandular organ has been an enigma for several decades as the adipocyte isn't supposed to be a resident in the milieu of the uterine corpus. In theory adipocyte presence is attributed to misplaced embryonic fat cells, metaplasia of the smooth muscles, proliferation of perivascular fat cells, inclusion of fat cells into uterus during surgery and degeneration of uterine connective tissue.<sup>7</sup> Whilst it is easier for the metaplasia model to explain the mixed lesions, pure lesions are harder to explain. Bolat et al attempted to draw an immunohistochemical profile of these tumours in an attempt to explain the histogenesis in the light of their findings.

Vimentin expression was found in the perivascular immature mesenchymal cells and tumoral smooth muscle cells as well as the Adipose cells in the tumour. Desmin was uniformly expressed in the perivascular mesenchymal cells and smooth muscles but inconsistently expressed in the adipose tissue. HMB 45 was negative in adipocytes but expressed in immature smooth muscle cells. Thus, concluding either transformation of immature mesenchymal or the stationed smooth muscle cells into adipocytes by progressive accumulation of intracellular lipid.<sup>8</sup>

These lesions present with variable symptoms most common being pain abdomen, fullness, bleeding per vaginum post menopause and irregular bleeding in menstruating women.<sup>1,9-11</sup>

This lesion presents a preoperative diagnostic challenge in terms of semblance to a leiomyoma. Clinically the signs and symptoms resemble any female genital malignancy or mass lesion thus creating an exhaustive list of differentials. Sonologically a leiomyoma appears to be of similar or increased echogenicity to myometrium whereas a lipoma appears as an echogenic lesion with a hypochoic rim representing the compressed myometrium. The rim may or may not be visualised and shows a case to case variability adding to the diagnostic uncertainty.<sup>3</sup> The tumour is better appreciated on CT Scan but with a limitation of being detected only when it is intramural. But if the tumour is exophytic or pedunculated the diagnosis may be difficult.<sup>8</sup> On MRI, Lipoma has high signal intensity on T1 and T2 weighted images. Moreover, the content of the tumour can be demonstrated by fat suppression techniques.<sup>12</sup> In a study by Ohguri T et al comparison between Lipomas and Liposarcomas of the uterus showed tumours without a non-adipose component and CT, MRI findings described above to conclusively be Lipomas.<sup>13</sup> Application of CT and MRI is governed by the restraints of cost, availability, pregnant state and technical expertise. Recent years have seen discovery of certain characteristic anomalies in the form of 12q15 and 6p21 leading to aberrations HMG genes. In a study by Tailini G et al analysis of 95 benign mesenchymal tumours including 20 lipomas showed alterations in the 12q15 and 6p21 spanning the HMG genes particularly the HMG-C and HMGI(Y) genes.<sup>14</sup> In summation the uniqueness of this tumour histologically and its camouflaging capabilities clinically and sonologically make it a deceptive customer.

**Conflicts of Interest:** None.

## References

1. Bandopadhyay A, Ray S. Calcified pure uterine lipoma mimicking myoma. *J Turkish-German Gynecol Assoc* 2010;11:113-114.
2. Gaspar IA. Lipoma of the uterus: a study and demonstration of the histogenesis of two cases. *J Med Soc NJ* 1980;77(3):179-182.
3. Chu C, Tang Y. Diagnostic challenge of lipomatous uterine tumors in three patients. *World J Radiol* 2012;4(2):58-62
4. Pathak V, Sukheeja D, Singh RK. Uterine intramural lipoma: A benign but rare entity. *Med J DY Patil Univ* 2017;10:384-385.

5. Pounder DJ. Fatty tumours of the uterus. *J Clin Pathol* 1982;35:1380-1383.
6. Serafini GI. Lipomatous tumors of the uterus: ultrasonographic findings in 11 cases. *J Ultrasound Causa Pedia* 2014;15(3):195-199.
7. Akturk Y, Kurt A, Akturk OM. Uterine Lipoma: A Rare Case Report and A Short Review of The Literature. *Causa Pedia* 2014;3:854.
8. Bolat F, Kayaselçuk F. Histogenesis of lipomatous component in uterine lipoleiomyomas. *Turk J Pathol* 2007;23(2):82-86.
9. Garg A, Sudhamani S, Kiri VM, Pandit AA. Pure lipoma of uterus: A case report with review of literature. *J Sci Soc* 2013;40:114-115.
10. Mohan KV, Radhika D. Pure uterine Lipoma. *J Case Rep* 2015;5(1):16-18.
11. Gangatirkar R, Gadre S. Uterine Lipoma: A Very Rare Cause of Postmenopausal Bleeding. *Obstet Gynecol Int J* 2018;9(1):00304.
12. Coumbaras M. Uterine lipoma: MRI features with pathologic correlation. *Abdom Imaging* 2005;30:239-241.
13. Ohguri T. Differential diagnosis of benign peripheral lipoma from well-differentiated liposarcoma on MR imaging: is comparison of margins and internal characteristics useful? *AJR* 2003;180(6):1689-1694.
14. Tallini G, Vanni R, Manfioletti G, Kazmierczak B, Faa G, Pauwels P, Bullerdiek J, Giancotti V, Van Den Berghe H, Dal Cin P. HMGI-C and HMGI(Y) immunoreactivity correlates with cytogenetic abnormalities in lipomas, pulmonary chondroid hamartomas, endometrial polyps, and uterine leiomyomas and is compatible with rearrangement of the HMGI-C and HMGI(Y) genes. *Lab Invest* 2000;80(3):359-369.

**How to cite this article:** Bajaj V, Singh KC, Chakravarty R. A rare case of intrauterine lipoma: A masterful masquerade. *Indian J Pathol Oncol* 2019;6(1):158-160.