

REVIEW

Tinea versicolor: an updated review

Alexander KC Leung¹, Benjamin Barankin², Joseph M Lam^{3,4}, Kin Fon Leong⁵, Kam Lun Hon^{6,7}

¹Department of Pediatrics, The University of Calgary, and The Alberta Children's Hospital, Calgary, Alberta, Canada; ²Toronto Dermatology Centre, Toronto, Ontario, Canada; ³Department of Pediatrics and Department of Dermatology and Skin Sciences, University of British Columbia, Vancouver, BC, Canada; ⁴BC Children's Hospital, Vancouver, BC, Canada; ⁵Pediatric Institute, Kuala Lumpur General Hospital, Kuala Lumpur, Malaysia; ⁶Department of Paediatrics, CUHK Medical Centre, Hong Kong Institute of Integrative Medicine, Hong Kong; ⁷Jockey Club School of Public Health and Primary Care, The Chinese University Hong Kong, Hong Kong

Abstract

Background: Tinea versicolor is a common superficial fungal infection of the skin with various clinical manifestations. This review aims to familiarize physicians with the clinical features, diagnosis and management of tinea versicolor. **Methods:** A search was conducted in July 2022 in PubMed Clinical Queries using the key terms "tinea versicolor" OR "pityriasis versicolor". The search strategy included all clinical trials, observational studies and reviews published within the past 10 years. **Results:** Tinea versicolor is caused by *Malassezia* species, notably *M. globosa*, *M. furfur* and *M. sympodialis*. The condition is characterized by scaly hypopigmented or hyperpigmented macules/patches, primarily located on the upper trunk, neck and upper arms. The diagnosis is usually based on characteristic clinical features. If necessary, a potassium hydroxide preparation test can be performed to reveal numerous short, stubby hyphae intermixed with clusters of spores. Most patients with tinea versicolor respond to topical antifungal therapy, which has a better safety profile (fewer adverse events, fewer drug interactions) and lower cost compared to systemic treatment and is therefore the treatment of choice. Oral antifungal therapy is typically reserved for patients with extensive

disease, frequent recurrences or disease that is refractory to topical therapy. Advantages of oral antifungal therapy include increased patient compliance, shorter duration of treatment, increased convenience, less time involved with therapy and reduced recurrence rates. On the other hand, oral antifungal therapy is associated with higher cost, greater adverse events and potential drug–drug interactions and is therefore not the first-line treatment for tinea versicolor. Long-term intermittent prophylactic therapy should be considered for patients with frequent recurrence of the disease. **Conclusion:** Selection of antifungal agents depends on several factors, including efficacy, safety, local availability, ease of administration, likelihood of compliance and potential drug interactions of the antifungal agent.

Keywords: evoked scale sign, fluconazole, itraconazole, ketoconazole, *Malassezia* species, pityriasis versicolor, selenium sulfide, terbinafine, zinc pyrithione.

Citation

Leung AKC, Barankin B, Lam JM, Leong KF, Hon KL. Tinea versicolor: an updated review. *Drugs Context*. 2022;11:2022–9–2. <https://doi.org/10.7573/dic.2022-9-2>

Introduction

Tinea versicolor (also known as pityriasis versicolor) is a common superficial fungal infection of the skin. Patients with tinea versicolor typically present with asymptomatic hypopigmented or hyperpigmented, finely scaled, oval or round macules/patches on the trunk and upper arms.¹ Patients occasionally report pruritus, particularly when the condition is more extensive.

The term 'versicolor' refers to the variable colours of the skin lesions that may occur in this disorder. Clinical manifestations of tinea versicolor are myriad, and the differential diagnoses are broad. This review aims to familiarize readers with the various clinical manifestations of tinea versicolor to avoid misdiagnosis, unnecessary investigations and mismanagement of the disease and will also highlight the correct management of this disease.

Methods

A search was conducted in July 2022 in PubMed Clinical Queries using the key terms “tinea versicolor” OR “pityriasis versicolor”. The search strategy included all clinical trials (including open trials, non-randomized controlled trials and randomized controlled trials), observational studies and reviews (including narrative reviews and meta-analyses) published within the past 10 years. Only papers published in the English literature were included in this review. The information retrieved from the search was used in the compilation of this article.

Review

Aetiopathogenesis

Tinea versicolor is caused by dimorphic lipophilic and lipid-dependent yeasts in the genus *Malassezia* (formerly known as *Pityrosporum*) species, notably *Malassezia globosa* (*M. globosa*), *M. furfur* and *M. sympodialis*.^{2–12} Other species that have been implicated include *M. restricta*, *M. obtuse*, *M. slooffiae*, *M. pachydermatis* and *M. japonica*.^{13–16} These yeasts are normal commensals on the skin surface.^{17,18} Skin colonization increases with age; 25% of children and almost 100% of adults are affected.¹⁹ Tinea versicolor occurs when the saprophytic yeast or budding form of the organism converts to the pathogenic hyphal or mycelial form. The fungal infection is localized to the stratum corneum. Predisposing factors for the conversion include a hot and humid environment, hyperhidrosis, application of oily lotion or cream to the skin, wearing of masks, excessive lipid-containing sebaceous secretions, malnutrition, poor general health, use of oral contraceptives, pregnancy, diabetes mellitus, use of topical or systemic corticosteroids, Cushing disease, *Helicobacter pylori* infection, immunodeficiency and genetic predisposition.^{20–36} A recent study showed oxidative stress has no role in the pathogenesis of tinea versicolor.²⁹

Hypopigmented lesions (more commonly noted in darker skin tones) seen in tinea versicolor are thought to result from damage to melanocytes and inhibition of tyrosinase by azelaic acid (a dicarboxylic acid) produced by the *Malassezia* species involved, small melanosomes and accumulation of lipid-like material in the stratum corneum blocking ultraviolet light.^{37–40} On the other hand, hyperpigmented lesions (more commonly noted in lighter skin tones) may result from a hyperaemic inflammatory response elicited by *Malassezia* species, more tonofilaments in the granulosum, a thicker stratum corneum and abnormally large melanosomes.^{8,38,41,42} Keratinase, produced by the *Malassezia* species, causes

loosening of the stratum corneum with subsequent scale formation.^{43,44}

Prevalence

Tinea versicolor occurs worldwide. The prevalence is very high in hot and humid climates.³⁵ In some tropical countries, the prevalence is as high as 50% whereas, in Sweden, the prevalence is as low as 0.5%.^{17,45,46} Tinea versicolor is most common amongst adolescents and young adults, presumably because of increased sebum production in individuals of these age groups.^{47–55} Although uncommon, the condition can occur in young children and elderly individuals.^{47–55} Rarely, tinea versicolor has been reported in infants including neonates.^{56–60} Tinea versicolor is slightly more common in men than in women presumably due to increased sebaceous activity in men.^{8,47,54} A positive family history of tinea versicolor is present in approximately 17% of affected individuals.^{61,62} The incidence of tinea versicolor appears to be the same in all races, though the change in skin pigmentation is more visually apparent in dark-skinned individuals.⁸

Histopathology

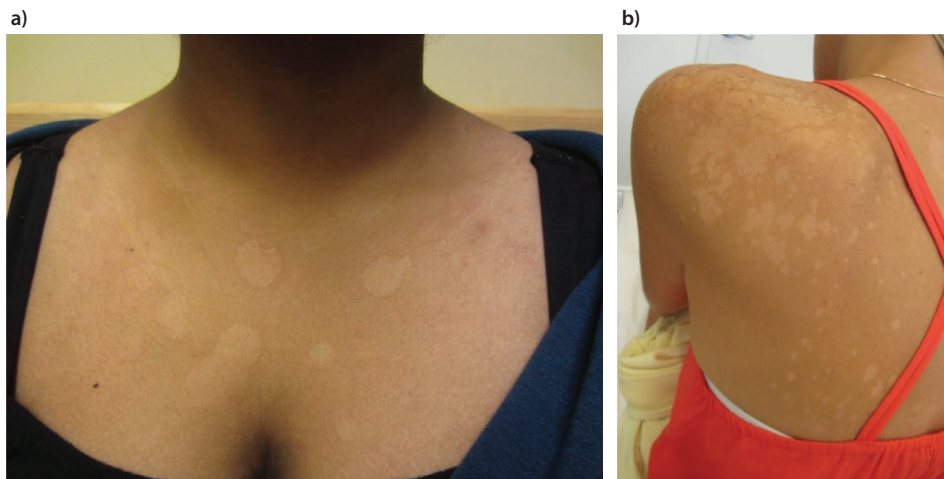
Histological findings include parakeratosis, hyperkeratosis, slight acanthosis and a mild superficial, perivascular infiltrate in the upper dermis.⁶³ Haematoxylin-eosin, methenamine silver or periodic acid–Schiff staining reveal the presence of yeast in a ‘spaghetti and meatballs’ pattern in the stratum corneum.^{63–65} Hyperpigmented lesions tend to contain more hyphae and spores than hypopigmented lesions.^{62,65,66} In hypopigmented lesions, the horny layer tends to be slightly hyperkeratotic and there may be a decrease in melanosomes in the stratum spinosum.^{39,45}

Clinical manifestations

Tinea versicolor is characterized by mildly scaly hypopigmented or hyperpigmented macules/patches, most commonly affecting areas of skin that are rich in sebum production such as the trunk (especially the upper part), neck, shoulders and upper arms (Figures 1–3A).^{19,21,24,67–69} Facial involvement is less common in adults. On the other hand, facial involvement is common in children and may be the only site involved (Figure 3B).^{19,70} The forehead is the usual site of facial involvement.^{71–74} Other sites of involvement, such as forearms and thighs, are less common (Figure 4).⁷⁵ Unusual sites of involvement include the scalp, eyelid, axilla, areola, periareolar area, antecubital fossae, popliteal fossa, pubis, groin, perineum, penile shaft and vulva.^{75–86}

Typically, lesions arise as multiple, small, oval or round, well-demarcated, round or oval macules.⁸ Smaller macules may have a powdery appearance because

Figure 1. Tinea versicolor presenting as multiple hypopigmented macules and patches on the chest (part a) and left shoulder and upper back (part b).

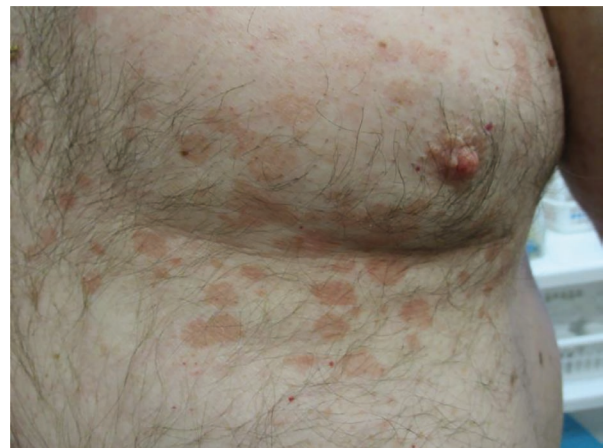

of flaking.⁸⁷ Over time, the macules enlarge radially and coalesce into patches or very superficial plaques.⁸ The lesions are covered with a fine scale, which is often difficult to appreciate upon clinical examination. On the other hand, the scale becomes more apparent when the lesion is stretched or scraped (the 'evoked scale sign') (Figure 5A,B).^{1,44,88,89} It should be noted that burned-out or treated lesions usually lack scale.⁹⁰ In patients with tinea versicolor, when the affected skin is wiped with a piece of wet cloth and scraped, it yields a considerable amount of dirty brown keratin. Tinea versicolor lesions are typically asymptomatic, although some patients complain of mild pruritus,⁴⁵ which may become worse in hot and humid conditions.

The eruption varies in colour from individual to individual, but each individual usually has lesions of a single hue. Lesions are usually evenly pigmented. In general, hyperpigmented lesions tend to occur in fair-skinned patients whereas hypopigmented lesions tend to occur in dark-skinned individuals.^{8,91} When hyperpigmented lesions occur in dark-skinned individuals, they are often grey-black, dark brown or black whereas these are often tan, light brown, red or pink in fair-skinned individuals.^{18,40} Lesions may become more apparent following exposure to the sun and are thus more noticeable during the summer months. Mixed hyperpigmented and hypopigmented lesions may be found, especially in the axilla and groin.^{8,41,91}

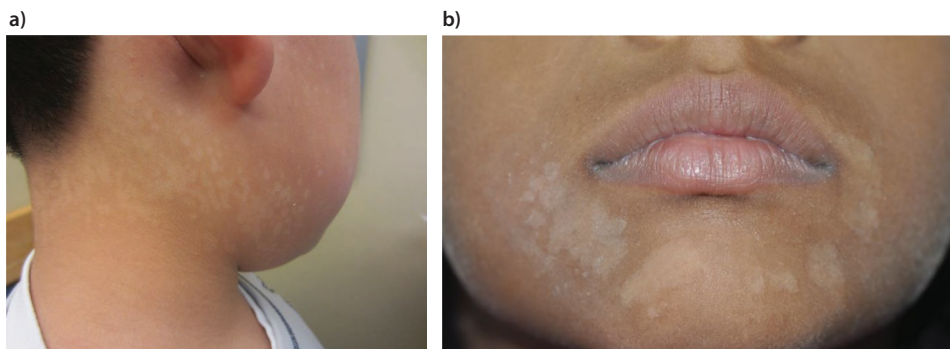
Several morphological variants have been described. An inverse form of tinea versicolor has been described, especially in patients who are immunocompromised.⁹² Some authors favour labelling this variant as 'tinea In-Versicolor'.⁹² In this variant, lesions tend to localize in the flexural areas (axilla, elbow, popliteal fossa and groin) and isolated areas of the extremities (Figure 6).⁹²⁻⁹⁴

Figure 2. Multiple erythematous macules and patches on the upper abdomen and chest.



Atrophying tinea versicolor typically presents with numerous, hypopigmented or erythematous/violaceous, round to oval, scaly lesions with a typically depressed appearance.⁹⁵⁻⁹⁸ Lesions tend to cluster and are generally uniform in size (a few millimetres to several centimetres) on the same patient and may have a wrinkled surface.⁹⁹ The atrophy is limited to the area affected by tinea versicolor.¹⁰⁰ The exact aetiology of the atrophy is not known. It is postulated that the atrophy may result from prolonged use of topical corticosteroids or delayed type IV hypersensitivity to epicutaneous antigens from the *Malassezia* species.¹⁰⁰⁻¹⁰⁴ Folliculocentric tinea versicolor involves the hair follicle and presents with asymptomatic hypopigmented or hyperpigmented macules located exclusively around the follicles^{105,106}; these macules may merge into patches.¹⁰⁶ The disorder

Figure 3. Multiple hypopigmented macules and patches on the neck and face of a 5-year-old child (part a) and on the face of a 10-year-old child (part b).



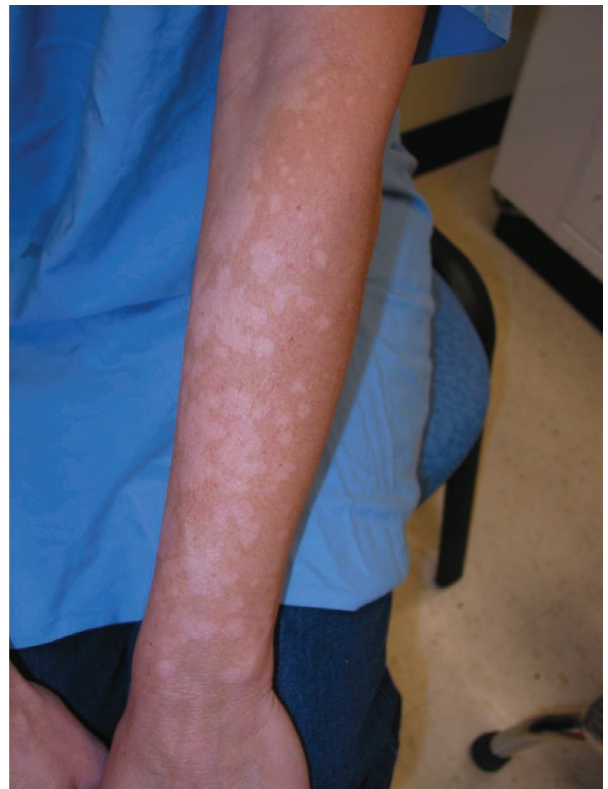is typically localized to the chest and back.^{106,107} A Wood lamp examination reveals folliculocentric fluorescence in hypopigmented areas.¹⁰⁷ Papular tinea versicolor presents with multiple, asymptomatic, monomorphic, red-brown papules (2–3 mm), which may or may not show the fine overlying scale.¹⁰⁵ They are usually found on the trunk.¹⁰⁵ Confetti-like tinea versicolor presents with asymptomatic confetti-like spots with slightly scaly surfaces (Figure 7). The spots are usually bilateral and symmetrically distributed. The formation of scaly, guttate and coalescent hypopigmented patches or plaques is unique in African Americans; this variant is colloquially known as acid skin.¹⁰⁸

Diagnosis

The diagnosis is usually clinical, based on the characteristic features (multiple hypopigmented or hyperpigmented, centrally coalescing, oval to round, finely scaling macules or patches and the 'evoked scale sign').³⁵ However, the varied presentations of tinea versicolor may be confusing to an inexperienced physician. Examination of the lesion with a Wood lamp (filtered ultraviolet light with a peak of 365 nm) may show gold-yellow, yellowish-green or coppery-orange fluorescence, although some lesions do not fluoresce.^{17,56} The fluorescence may include areas surrounding clinically visible lesions, suggesting that the fungal infection is spreading.¹⁷

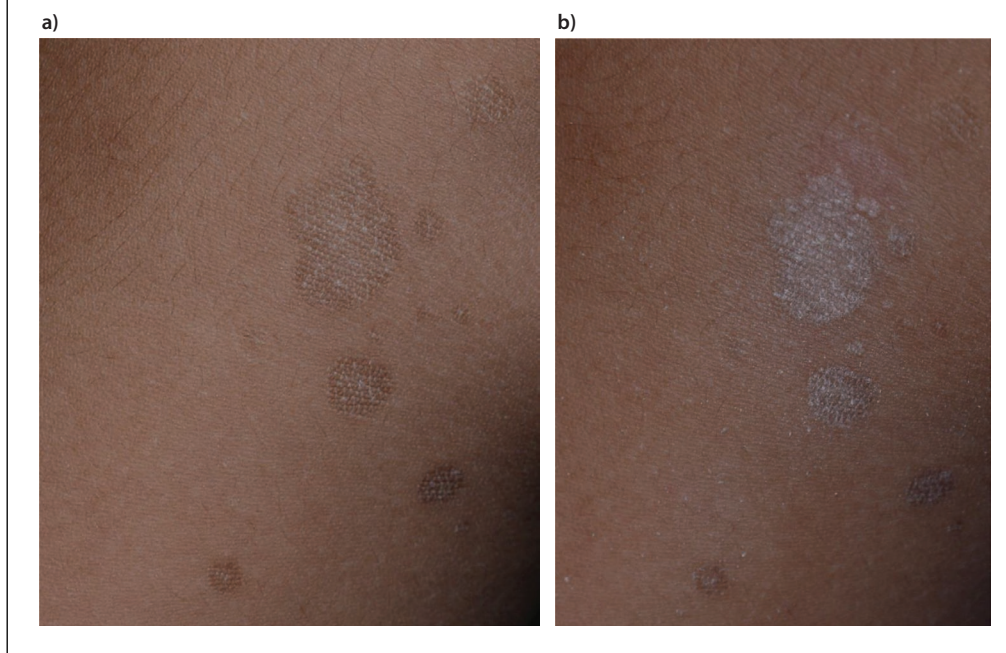
Dermoscopy is a useful ancillary tool for the diagnosis of tinea versicolor.^{109–114} Typical dermoscopic findings include alteration in the background pigmentation, a 'contrast halo' sign (a ring of hypopigmentation surrounding the primary lesion of increased pigmentary network in a hyperpigmented lesion or a ring of increased pigmentation surrounding the primary lesion of decreased pigmentary network in hypopigmented lesion), fine scale on the involved skin, folliculocentricity and hypopigmentation of the invaded hair follicle.^{110–114}

Figure 4. Multiple hypopigmented macules and patches on the left forearm.



If necessary, a potassium hydroxide (KOH) preparation test can be performed; examination of scrapings from the border of the lesion soaked with 10–15% KOH reveals numerous short, stubby hyphae intermixed with clusters of spores (the so-called 'spaghetti and meatballs' appearance) (Figure 8).⁵¹ KOH helps to dissolve the keratin and debris so that the hyphae and spores can be readily visible by microscopy. The border of the lesion contains the highest number of fungi. Because the standard

Figure 5. Hyperpigmented macules with minimal desquamation on the upper back (part a) and with prominent desquamation on the upper back after the skin lesion was scrapped (the evoked scale sign, part b).

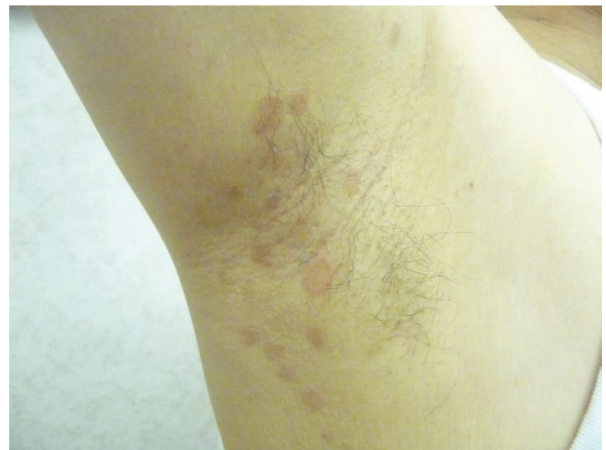

KOH mount does not show a colour contrast, ink blue, Parker blue-black ink, methylene blue, chlorazol black E, Swartz-Lamkin, Swartz-Medrik or Chicago Sky Blue (CSB) 6B staining may be added for better visualization of the causative organism.^{35,115,116} Thus far, the contrast stain containing 1% CSB 6B has the greatest specificity and sensitivity.¹¹⁵

Differential diagnosis

The differential diagnoses are broad, especially those with unusual presentations. The differential diagnosis of hypopigmented lesions of tinea versicolor includes pityriasis alba, nevus anemicus, nevus depigmentosus, idiopathic guttate hypomelanosis, eruptive hypomelanosis, progressive macular hypomelanosis, leukoderma punctate, hypomelanosis of Ito, vitiligo, ash-leaf spot in tuberous sclerosis, corticosteroid-induced hypopigmentation, arsenicosis, leprosy, hypopigmented mycosis fungoides and post-inflammatory hypopigmentation.¹¹⁷⁻¹²⁴ On the other hand, hyperpigmented lesions of tinea versicolor should be differentiated from tinea corporis, pityriasis rosea, pityriasis rotunda, tinea imbricata, acanthosis nigricans, terra firma-forme dermatosis, café au lait macules, ephelides, solar lentigines, melasma, erythrasma, guttate psoriasis, nummular eczema, seborrheic dermatitis, contact dermatitis, post-inflammatory hyperpigmentation, type 1 (classic adult) pityriasis rubra pilaris, secondary syphilis, confluent and reticulated papillomatosis (also known as Gougerot-Carteaud syndrome), and epidermodysplasia verruciformis (also

Figure 6. Hyperpigmented macules in the axillary region of a 17-year-old male with tinea *InVersicolor*.



known as Lewandowsky-Lutz dysplasia).¹²⁵⁻¹³⁸ The distinctive features of many of these conditions help to differentiate them from tinea versicolor.

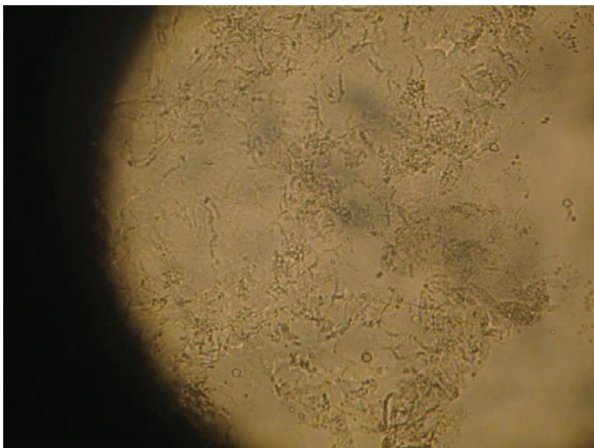
Complications

Skin discolouration can be cosmetically unsightly and socially embarrassing especially if it occurs in exposed areas of the body. This may have an adverse effect on quality of life. The discolouration of the skin (without

Figure 7. Confetti-like spots on the left arm, left lateral upper chest and armpit of a child with confetti-like tinea versicolor.

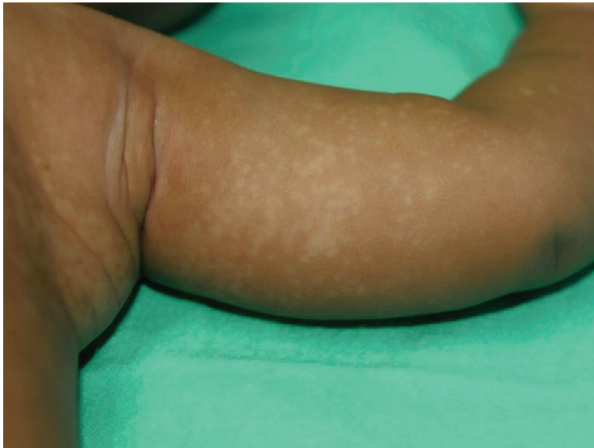

Figure 8. KOH preparation of tinea versicolor showing numerous short, stubby, hyphae intermixed with clusters of spores (the so-called 'spaghetti and meatballs' appearance).



overlying scaling) may persist for weeks to months even after completion of successful therapy. The disappearance of the scale is evidence that the hyphal yeast has been eradicated.⁴⁴ A preliminary study showed that topical application of cycloserine, a transaminase 1 inhibitor, to the hyperpigmented lesions of tinea versicolor twice a day for 5 days resulted in complete clearing of the hyperpigmentation.¹³⁹ Well-designed, large-scale, multicentre, randomized, placebo-controlled trials are needed to confirm or refute this finding.

Hair thinning and/or hair loss within the tinea versicolor lesions has been reported.¹⁴⁰ In a study of 39 patients with tinea versicolor, hair thinning and/or hair loss within the tinea versicolor lesions occurred in 24 (61.5%) patients.¹⁴⁰

Hair thinning and/or hair loss occurred most commonly on the forearms, abdomen, neck and, in men, the beard area.

Prognosis

The prognosis is good. Mycological cure is usually achieved soon after antifungal treatment. Tinea versicolor tends to persist for years if left untreated.^{141–143} The disorder has a high recurrence rate, especially in patients with a positive family history of tinea versicolor.^{51,63,144,145} Framil et al. followed 102 patients with clinical and laboratory diagnosis of tinea versicolor for one year.¹⁴⁵ After appropriate treatment, 33 (33.35%) patients did not have any relapsing episodes, 54 (52.94%) patients had one to four relapsing episodes and 15 (14.7%) patients had more than four relapsing episodes.¹⁴⁵ Patients with a positive family history of tinea versicolor also have a longer duration of the disease.⁵¹ Relapse rates as high as 80% following treatment have been reported.¹⁴⁶

Management

Most patients with tinea versicolor respond to topical antifungal therapy (Box 1). Additionally, topical antifungal therapy has a better safety profile (fewer adverse events, fewer drug interactions) and lower cost compared to systemic treatment and is therefore the treatment of choice. Oral antifungal therapy is typically reserved for patients with extensive disease, frequent recurrences or disease that is refractory to topical therapy (Box 1). For resistant or stubborn cases, combining oral and topical therapies may be considered. Alternative and complementary therapies are still used in many parts of the world.^{141,142}

Topical antifungals

Many topical antifungals have proved to be effective in the treatment of tinea versicolor. Various antifungal preparations are available, including shampoos, foams, gels, lotions and creams and are usually applied once to twice daily.¹ Shampoo is preferred when a large percentage of the body surface area is involved. Treatment regimens range from a few days to 4 weeks.¹¹⁴⁷ A systematic review of 93 controlled trials ($n=8327$) showed that most topical antifungal medications used to treat tinea versicolor are effective compared to placebo, with numbers needed to treat of 1–3.¹⁴⁷ Additionally, greater cure rates can be achieved with higher concentrations of active ingredients in the topical antifungal medications and longer duration of treatment.^{147,148} The most common side-effects of topical antifungal agents are skin irritation and contact allergy.³⁵

Azoles

Topical azole drugs (for example, ketoconazole, econazole, eberconazole, efinaconazole, bifonazole, luliconazole,

Box 1. Treatment options for tinea versicolor.

- A. Topical antifungals
 1. Azoles (for example, ketoconazole, econazole, eberconazole, efinaconazole, bifonazole, luliconazole, clotrimazole, miconazole, sertaconazole, sulconazole, oxiconazole, fenticonazole, tioconazole, fluconazole and dapaconazole)
 2. Terbinafine
 3. Naftifine
 4. Butenafine
 5. Ciclopirox olamine
 6. Non-specific topical antifungal agents (for example, selenium sulfide, zinc pyrithione, propylene glycol, Whitfield ointment, sulfur plus salicylic acid and benzoyl peroxide)
- B. Oral antifungals
 1. Itraconazole
 2. Fluconazole
- C. Laser and photodynamic therapies
- D. Alternative therapies

clotrimazole, miconazole, sertaconazole, sulconazole, oxiconazole, fenticonazole, tioconazole, fluconazole and dapaconazole) have become an important treatment class for tinea versicolor.^{149–165} This group of antifungal agents are fungistatic and works by inhibiting the P-450-dependent enzyme lanosterol 14- α -demethylase, which is involved in the biosynthesis of ergosterol.^{166,167} Ergosterol is an important structural component of fungal cell membranes.^{62,166} Impairment of biosynthesis of ergosterol may limit cell function and cell growth.^{62,166} Randomized clinical trials have supported the efficacy of various topical azole antifungal agents.^{149–165} Of the topical azole antifungal agents, ketoconazole has been most studied for the treatment of tinea versicolor. In addition to its ability to block the synthesis of ergosterol, ketoconazole also has sebum-lowering effects by inhibiting androgenesis, anti-inflammatory effects by inhibiting 5-lipoxygenase and barrier-restoring effects by inhibiting hyperproliferation of keratinocytes.^{166,168–170} As ketoconazole is highly lipophilic, it concentrates at sites of tinea versicolor, thereby further increasing its efficacy.¹⁶⁶ A 2019 systematic view of 40 randomized controlled trials ($n=4566$) focusing on the use of topical ketoconazole for the treatment of *Malassezia*-related conditions, such as tinea versicolor, showed that the efficacy rate of topical ketoconazole for the treatment of tinea versicolor was 71–89%.¹⁶⁶ Topical azole drugs have a favourable safety. Adverse events are usually mild and uncommon and include skin dryness, irritation, pruritus, burning sensation and erythema.¹⁴⁷ Rarely, allergic contact dermatitis may occur.¹⁶⁶

Studies have shown that combination therapies using 2% ketoconazole cream and 1% adapalene gel are more efficacious in the treatment of tinea versicolor than ketoconazole cream alone.^{171,172} To further improve the

efficacy of topical ketoconazole, future drug development should focus on improving topical delivery to allow better permeation of drugs into skin by using nanostructured lipid carriers, nanoparticles, microemulsions, copolymeric micelles, niosomes and microemulsions.^{156,173–176} In this regard, the development of topical gels containing fluconazole-loaded solid lipid nanoparticles allows fluconazole to be used topically as the product exhibits skin penetration as a result of large particle surface area and film formation, enhancing contact between fluconazole and skin.¹⁵⁶ Recently, it has been shown that itraconazole-loaded aspasomal cream has a higher efficacy in the treatment of tinea versicolor than non-formulated itraconazole cream alone.¹⁷⁷

Terbinafine

Terbinafine, an allylamine antifungal, works by inhibiting squalene epoxidase, thereby blocking the biosynthesis of ergosterol.^{87,163,178} The accumulation of squalene accounts for its fungicidal activity whilst ergosterol deficiency accounts for its fungistatic activity.¹⁶³ The effectiveness of topical terbinafine in the treatment of tinea versicolor has been demonstrated in many double-blind, randomized, placebo-controlled studies.^{178–181}

There are very few good quality studies comparing the efficacy of topical terbinafine with topical azole drugs for the treatment of tinea versicolor. Most trials are underpowered to detect clinically meaningful differences. In an open clinical trial, 60 adults with tinea versicolor were randomized to receive either eberconazole 1% cream or terbinafine 1% cream once daily for 2 weeks.¹⁶³ At the end of the treatment period, there was a significant improvement in all the clinical parameters in both groups. Clinical cure was present in 80% of patients in the eberconazole group versus 63% of patients in the terbinafine group.

Mycological cure was achieved in 100% of patients in the eberconazole group *versus* 97% of patients in the terbinafine group. No adverse events were noted. No relapse was seen in patients treated with eberconazole but one patient treated with terbinafine had a relapse at the end of 8 weeks. The authors concluded that both terbinafine and eberconazole were efficacious and safe in the treatment of tinea versicolor but better response was observed in patients treated with eberconazole. In another study, 110 patients (≥ 14 years of age) with a clinical diagnosis of tinea versicolor confirmed by KOH microscopy were randomized to receive either terbinafine 1% cream ($n=55$) or ketoconazole 2% cream ($n=55$) twice daily.¹⁸² Patients with negative mycological examination either with clearance of skin lesions or presence of mild residual skin lesions were considered cure. Cure rates at the end of the second, fourth and eighth weeks of treatment were 72% and 64.3%, 81.2% and 69%, and 70.8% and 61.9% for the terbinafine group and the ketoconazole groups, respectively. The authors concluded that there were no significant statistical differences between the terbinafine group and the ketoconazole group with regard to the cure and recurrence rates. However, the numbers of patients were higher and the recurrent cases were lower in those treated with topical terbinafine. Chopra et al. randomized 50 patients with tinea versicolor confirmed by KOH microscopy to receive either terbinafine 1% cream ($n=25$) or ketoconazole 2% cream ($n=25$) once daily for 2 weeks.¹⁸³ At the end of treatment, the clinical and mycological cure rate was 96% for patients treated with topical terbinafine and 88% for patients treated with topical ketoconazole; no adverse events were reported. At 3 months of follow-up, the relapse rate was 8.33% in patients treated with topical terbinafine and 13.53% in patients treated with topical ketoconazole.

Naftifine

Naftifine is a synthetic allylamine derivative with broad-spectrum antifungal activity.¹⁸⁴ The medication works by blocking the biosynthesis of ergosterol via inhibition of squalene epoxidase, with resulting accumulation of squalene, increase in fungal cell membrane fragility and permeability, and inhibition of fungal cell growth.¹⁸⁴ As naftifine is highly lipophilic, it can penetrate efficiently into the epidermis when applied topically.¹⁸⁴ Open studies have shown that topical naftifine is safe and efficacious in the treatment of tinea versicolor.^{185–187} Well-designed, large-scale, randomized, double-blind and placebo-controlled studies are necessary to further elucidate its clinical efficacy and safety.

Butenafine

Butenafine, a synthetic benzylamine antifungal agent with fungicidal activity, has also been used topically for the treatment of tinea versicolor.¹⁸⁸ The medication

inhibits squalene epoxidation with resultant blockage of ergosterol biosynthesis. Small randomized controlled trials have shown the clinical efficacy of topical butenafine in the treatment of tinea versicolor.^{189–190} In a randomized, double-blind, parallel-group trial, the rate of mycological cure in patients with tinea versicolor treated with topical butenafine and topical bifonazole was 87.5% and 83.3%, respectively, after 2 weeks of treatment.¹⁸⁹ The rate of effective clinical response in patients with tinea versicolor treated with butenafine and bifonazole was 91.7% and 83.3%, respectively. There was no significant statistical difference in terms of mycological cure and effective clinical response between treatment with topical butenafine and topical bifonazole. Well-designed, large-scale, randomized, double-blind and placebo-controlled studies are necessary to determine the safety and efficacy of topical butenafine in treating tinea versicolor.

Ciclopirox olamine

Ciclopirox olamine is a hydroxypyridone with broad-spectrum antifungal activity.^{62,191} The medication works by inhibiting the transport of essential elements, which is required for the synthesis of the fungal cell membrane.⁶³ Ciclopirox olamine also interferes with the synthesis of DNA, RNA and protein. Ciclopirox olamine has been shown to be safe and effective for the treatment of tinea versicolor in several studies.^{191–193} The safety and efficacy of topical ciclopirox olamine in the treatment of tinea versicolor need to be substantiated by well-designed, large-scale, randomized, double-blind and placebo-controlled studies.

Non-specific topical antifungal agents

Non-specific topical antifungal agents for the treatment of tinea versicolor include selenium sulfide, zinc pyrithione, propylene glycol, Whitfield ointment, sulfur plus salicylic acid and benzoyl peroxide. These topical agents do not act specifically against *Malassezia* species. Their mode of action is to remove dead, infected stratum corneum either physically and/or chemically.¹⁹⁴

Selenium sulfide, available as a shampoo, lotion and cream in 1–2.5% concentrations, is safe and effective in the treatment of tinea versicolor.^{147,195–197} Studies have shown that the success rate of selenium sulfide shampoo in the treatment of tinea versicolor is comparable to that of topical bifonazole and econazole.^{198,199} Advantages of selenium sulfide include over-the-counter availability, low cost and convenient application. Disadvantages include irritation of the skin, unpleasant odour, staining of clothes and bedding, and a high relapse rate.^{195,196}

The efficacy of zinc pyrithione 1% shampoo *versus* its vehicle in the treatment of tinea versicolor has been shown in an open trial²⁰⁰ as well as in a double-blind controlled

trial.²⁰¹ In the latter, 20 patients with tinea versicolor were treated with either zinc pyrithione 1% shampoo or the shampoo base for 5 minutes per day for 2 weeks.²⁰¹ At the end of the study, all 20 patients treated with zinc pyrithione 1% shampoo had clearing of the tinea versicolor lesions compared to none of the patients in the shampoo base group.

Propylene glycol is a keratolytic agent. Faergemann et al. treated 20 patients with tinea versicolor with propylene glycol 50% in water daily for 2 weeks.²⁰² At the end of treatment, all 20 patients were cured.

Whitfield ointment consists of 3% salicylic acid and 6% benzoic acid in an emulsifying ointment.^{153,203} Salicylic acid is keratolytic whereas benzoic acid is fungistatic.¹⁷ Whitfield ointment has been shown to be effective in the treatment of tinea versicolor in a limited number of studies.^{153,203}

A combination of sulfur and salicylic acid has been shown to be effective in the treatment of tinea versicolor in a small number of studies.^{204,205} The combination can be in the form of 2% micropulverized sulfur and 2% salicylic acid in a shampoo base.^{204,205} The formulation is cosmetically pleasant and safe.²⁰⁴

Benzoyl peroxide has been used with success in the treatment of tinea versicolor.^{206–208} In three studies, the vehicle for benzoyl peroxide was propylene glycol, which by itself is effective in the treatment of tinea versicolor.^{206–208} As such, it is not certain whether the beneficial effect is due to benzoyl peroxide or propylene glycol. It is possible that benzoyl peroxide and propylene glycol may have a synergistic effect in the treatment of tinea versicolor.

Oral antifungals

Oral antifungals are usually reserved for treating severe, widespread, recalcitrant or recurrent tinea versicolor.¹⁷ Advantages of oral antifungal therapy include increased patient compliance, shorter duration of treatment, increased convenience, less time involved with treatment and reduced recurrence rates.^{17,209} On the other hand, oral antifungal therapy is associated with higher cost, greater adverse events, and potential drug–drug interactions and is therefore not the first-line treatment of tinea versicolor, especially in children.¹ Oral azole antifungals, such as itraconazole and fluconazole, are the preferred systemic agents.^{210,211} Adverse events associated with the use of oral antifungals include fatigue, malaise, headache, cutaneous eruption, pruritus, dyspepsia, nausea, vomiting, abdominal pain, diarrhoea, hypertension, congestive cardiac failure, thrombocytopenia, hypokalaemia, albuminuria, hypertriglyceridemia and abnormal liver function.^{147,212,213}

Oral itraconazole

Oral itraconazole, a triazole derivative with strong keratophilic and lipophilic properties, is highly effective for the treatment of tinea versicolor^{143,210,214}; the absorption of itraconazole is enhanced by food.^{17,215} The recommended dose is 200 mg per day for 5–7 days.^{163,141,142} Adverse events are uncommon.²¹⁶ Rarely, congestive heart failure and hepatotoxicity have been reported.³⁵ Oral itraconazole should therefore be avoided in patients with a history of congestive heart failure or in patients with active hepatic disease.³⁵ As itraconazole inhibits the enzyme cytochrome P450-dependent system, the medication may cause drug–drug interactions. As such, oral itraconazole should not be given to patients who are on astemizole or cisapride for fear of cardiovascular adverse events.³⁵

Oral fluconazole

Oral fluconazole, a triazole antifungal, is also highly effective for the treatment of tinea versicolor through the inhibition of cytochrome P450-dependent ergosterol synthesis.^{217–219} When administered orally, fluconazole can persist in the stratum corneum for approximately 2 weeks following administration.²¹⁹ The recommended dose is 300 mg once weekly for 2–4 weeks.^{163,211} Because fluconazole has little affinity for mammalian cytochromes, the antifungal has low toxicity. Serious adverse events are rare.³⁵ As fluconazole inhibits the cytochrome P450-dependent system, the medication should likewise be avoided in patients treated with astemizole or cisapride for fear of cardiovascular adverse events.³⁵

Oral ketoconazole

Oral ketoconazole at a dose of 200 mg daily for 10 days is also effective for the treatment of tinea versicolor.¹⁴⁷ The risk of hepatotoxic adverse events associated with oral ketoconazole is about 1 in 500 and therefore outweighs its potential benefits.^{220,221} Because of the risk of hepatotoxicity, adrenal insufficiency and multiple drug–drug interactions, oral ketoconazole should no longer be prescribed.^{1,35,87}

Oral terbinafine

Oral terbinafine is not effective in the treatment of tinea versicolor.⁸⁷ Terbinafine is not excreted in sweat and fungicidal levels of terbinafine cannot be achieved in the stratum corneum with oral administration of the medication.⁸⁷

Oral griseofulvin

Oral griseofulvin is not effective for the treatment of tinea versicolor.^{17,43}

Laser and photodynamic therapies

A limited number of studies reported the successful treatment of tinea versicolor with 308-nm excimer

laser, narrow-band ultraviolet (UV)-B phototherapy, 5-aminolevulinic acid photodynamic therapy and methylene blue photodynamic therapy.^{222–225} Well-designed, large-scale, multicentre, randomized, placebo-controlled trials are needed to confirm or refute these findings.

Alternative therapies

A wide variety of alternative medicines have been shown to have some therapeutic effects on tinea versicolor. In some cultures, alternative therapies are popular for the treatment of tinea versicolor. These include topical application of beeswax and honey,²²⁶ essential oils of *Cymbopogon citratus*,²²⁷ quince seed mucilage hydrogel decorated with essential oils of *Nigella sativa*, *Citrus sinensis* and *Cinnamon verum*,²²⁸ polyherbal Unani formulation,²²⁹ *Pentas longiflora* leaf extract,²³⁰ *Acalypha wilkesiana* leaf extract,²³¹ *Artemisia sieberi* shrub extract,¹⁸² nitric oxide-liberating cream²³² and irradiated human amniotic membrane in combination with tea tree oil.²³³ None of these treatments have yet been subjected to rigorous studies nor randomized clinical trials.

Prophylactic treatment

The relapse rate is high because *Malassezia* species are normal commensals on the skin surface.⁸⁷ Good personal hygiene may limit recurrences to a certain extent. Long-term intermittent prophylactic therapy should be considered for patients with frequent recurrence of the disease who desire treatment, especially during the warmer months of the year.⁸⁷ Unfortunately, research studies evaluating the efficacy of prophylactic antifungal treatment are scarce. Prophylactic administration of topical ketoconazole 2%, clotrimazole 1% or selenium

sulfide 2.5% shampoo applied to the whole body for 10 minutes once a month may lead to decreased relapse rate of tinea versicolor.¹⁶⁶ An alternative is to prophylactically administer an oral antifungal agent such as itraconazole, especially if topical antifungal prophylaxis is not successful. Oral itraconazole is easy to administer and less time-consuming and thereby has better compliance.⁶³ The recommended dose of itraconazole for prophylaxis is 200 mg twice a day once per month.^{1,216}

Conclusion

Tinea versicolor is a common superficial fungal infection of the skin caused by *Malassezia* species. Because the clinical manifestations of tinea versicolor are myriad, clinical acumen is essential to make the correct diagnosis. As tinea versicolor is often a chronic and recurrent disease, repetitive treatment courses are often necessary. A wide range of antifungal agents are effective in the treatment of tinea versicolor. In general, topical antifungal agents are the first-line treatment of tinea versicolor as there are fewer adverse events associated with their use. Oral antifungal agents are usually reserved for severe, widespread, recalcitrant or recurrent disease. Apart from considering the severity and extensiveness of tinea versicolor, patient age, and patient and physician preferences, the selection of antifungal agents depends on a number of factors, including the efficacy, safety, local availability, ease of administration, likelihood of compliance and potential drug interactions of the antifungal agent. In clinical practice, it is often the patient preferences and the physician experience that dictate the selected treatment.

Contributions: AKCL is the principal author. BB, JML, KFL and KLH are coauthors who contributed and helped with the drafting of this manuscript. All named authors meet the International Committee of Medical Journal Editors (ICMJE) criteria for authorship for this article, take responsibility for the integrity of the work and have given their approval for this version to be published. All named authors meet the International Committee of Medical Journal Editors (ICMJE) criteria for authorship for this article, take responsibility for the integrity of the work as a whole and have given their approval for this version to be published.

Disclosure and potential conflicts of interest: AKCL and KLH are associate editors of *Drugs in Context* and confirm that this article has no other conflicts of interest otherwise. This manuscript was sent out for independent peer review. The International Committee of Medical Journal Editors (ICMJE) Potential Conflicts of Interests form for the authors is available for download at: <https://www.drugsincontext.com/wp-content/uploads/2022/10/dic.2022-9-2-COI.pdf>

Acknowledgements: None.

Funding declaration: There was no funding associated with the preparation of this article.

Copyright: Copyright © 2022 Leung AKC, Barankin B, Lam JM, Leong KF, Hon KL. Published by *Drugs in Context* under Creative Commons License Deed CC BY NC ND 4.0, which allows anyone to copy, distribute and transmit the article provided it is properly attributed in the manner specified below. No commercial use without permission.

Correct attribution: Copyright © 2022 Leung AKC, Barankin B, Lam JM, Leong KF, Hon KL. <https://doi.org/10.7573/dic.2022-9-2>. Published by *Drugs in Context* under Creative Commons License Deed CC BY NC ND 4.0.

Article URL: <https://www.drugsincontext.com/tinea-versicolor-an-updated-review>

Correspondence: Alexander KC Leung, The University of Calgary, The Alberta Children's Hospital, #200, 233 – 16th Avenue NW, Calgary, Alberta, Canada T2M 0H5. Email: aleung@ucalgary.ca

Provenance: Invited; externally peer reviewed.

Submitted: 9 September 2022; **Accepted:** 4 October 2022; **Published:** 14 November 2022.

Drugs in Context is published by BioExcel Publishing Ltd. Registered office: 6 Green Lane Business Park, 238 Green Lane, New Eltham, London, SE9 3TL, UK.

BioExcel Publishing Limited is registered in England Number 10038393. VAT GB 252 7720 07.

For all manuscript and submissions enquiries, contact the Editorial office editorial@drugsincontext.com

For all permissions, rights and reprints, contact David Hughes david.hughes@bioexcelpublishing.com

References

1. Goldstein BG, Goldstein AO. Tinea versicolor (pityriasis versicolor). In: Dellavalle RP, Levy ML, Rosen T, eds. Waltham, MA: UpToDate. <https://www.uptodate.com/contents/tinea-versicolor-pityriasis-versicolor>. Accessed July 26, 2022.
2. Aghaei Gharehbolagh S, Mafakher L, Salehi Z, et al. Unveiling the structure of GPI-anchored protein of *Malassezia globosa* and its pathogenic role in pityriasis versicolor. *J Mol Model*. 2021;27(9):246. <https://doi.org/10.1007/s00894-021-04853-7>
3. Archana BR, Beena PM, Kumar S. Study of the distribution of *Malassezia* Species in patients with pityriasis versicolor in Kolar Region, Karnataka. *Indian J Dermatol*. 2015;60(3):321. <https://doi.org/10.4103/0019-5154.156436>
4. Awad AK, Al-Ezzy AIA, Jameel GH. Phenotypic identification and molecular characterization of *Malassezia* Spp. isolated from pityriasis versicolor patients with special emphasis to risk factors in Diyala Province, Iraq. *Open Access Maced J Med Sci*. 2019;7(5):707–714. <https://doi.org/10.3889/oamjms.2019.128>
5. Diongue K, Kébé O, Faye MD, et al. MALDI-TOF MS identification of *Malassezia* species isolated from patients with pityriasis versicolor at the seafarers' medical service in Dakar, Senegal. *J Mycol Med*. 2018;28(4):590–593. <https://doi.org/10.1016/j.mycmed.2018.09.007>
6. Framil VM, Melhem MS, Szeszs MW, Corneta EC, Zaitz C. Pityriasis versicolor circinata: isolation of *Malassezia sympodialis* – Case report. *An Bras Dermatol*. 2010;85(2):227–228. <https://doi.org/10.1590/s0365-05962010000200015>
7. Hamdino M, Saudy AA, El-Shahed LH, Taha M. Identification of *Malassezia* species isolated from some *Malassezia* associated skin diseases. *J Mycol Med*. 2022;32(4):101301. <https://doi.org/10.1016/j.mycmed.2022.101301>
8. Kallini JR, Riaz F, Khachemoune A. Tinea versicolor in dark-skinned individuals. *Int J Dermatol*. 2014;53(2):137–141. <https://doi.org/10.1111/ijd.12345>
9. Lyakhovitsky A, Shemer A, Amichai B. Molecular analysis of *Malassezia* species isolated from Israeli patients with pityriasis versicolor. *Int J Dermatol*. 2013;52(2):231–233. <https://doi.org/10.1111/j.1365-4632.2012.05595.x>
10. Pedrosa AF, Lisboa C, Faria-Ramos I, et al. Epidemiology and susceptibility profile to classic antifungals and over-the-counter products of *Malassezia* clinical isolates from a Portuguese University Hospital: a prospective study. *J Med Microbiol*. 2019;68(5):778–784. <https://doi.org/10.1099/jmm.0.000966>
11. Vest BE, Krauland K. *Malassezia furfur*. In: StatPearls [Internet]. Treasure Island, FL: StatPearls Publishing. <https://www.ncbi.nlm.nih.gov/books/NBK553091/>. Accessed October 13, 2022.
12. Wang K, Cheng L, Li W, et al. Susceptibilities of *Malassezia* strains from pityriasis versicolor, *Malassezia* folliculitis and seborrheic dermatitis to antifungal drugs. *Heliyon*. 2020;6(6):e04203. <https://doi.org/10.1016/j.heliyon.2020.e04203>

13. Duy Nguyen B, Thi Thanh Vo H, Dinh Thi Thanh M, et al. Epidemiological characterization of pityriasis versicolor and distribution of *Malassezia* species among students in Hai Phong city, Vietnam. *Curr Med Mycol*. 2020;6(2):11–17. <https://doi.org/10.18502/CMM.6.2.2838>
14. Ogunbiyi AO, George AO. Pityriasis versicolor: current concepts in aetiology and management. *Niger Postgrad Med J*. 2005;12(3):183–188.
15. Petry V, Tanhausen F, Weiss L, Milan T, Mezzari A, Weber MB. Identification of *Malassezia* yeast species isolated from patients with pityriasis versicolor. *An Bras Dermatol*. 2011;86(4):803–806. <https://doi.org/10.1590/s0365-05962011000400032>
16. Romero-Sandoval K, Costa AA, Teixeira Sousa MG, et al. Recurrent and disseminated pityriasis versicolor: a novel clinical form consequent to *Malassezia*–host interaction? *Med Hypotheses*. 2017;109:139–144. <https://doi.org/10.1016/j.mehy.2017.10.013>
17. Gupta AK, Bluhm R, Summerbell R. Pityriasis versicolor. *J Eur Acad Dermatol Venereol*. 2002;16(1):19–33. <https://doi.org/10.1046/j.1468-3083.2002.00378.x>
18. Kurniadi I, Hendra Wijaya W, Timotius KH. *Malassezia* virulence factors and their role in dermatological disorders. *Acta Dermatovenerol Alp Pannonica Adriat*. 2022;31(2):65–70.
19. Leung AKC. Pityriasis versicolor. In: Lang F, ed. *The Encyclopedia of Molecular Mechanisms of Disease*. Berlin: Springer-Verlag; 2009:1652–1654. ISBN: 978-3-540-67136-7
20. Aghaei Gharehbolagh S, Kordbacheh P, Hashemi SJ, et al. MGL_3741 gene contributes to pathogenicity of *Malassezia globosa* in pityriasis versicolor. *Mycoses*. 2018;61(12):938–944. <https://doi.org/10.1111/myc.12840>
21. Alam HS, Ward JM, Davis LS. Generalized tinea versicolor following initiation of ixekizumab therapy. *JAAD Case Rep*. 2021;18:54–56. <https://doi.org/10.1016/j.jidcr.2021.10.008>
22. Balestri R, Rech G, Piraccini BM, et al. Pityriasis versicolor during anti-TNF- α monoclonal antibody therapy: therapeutic considerations. *Mycoses*. 2012;55(5):444–446. <https://doi.org/10.1111/j.1439-0507.2012.02170.x>
23. Borelli D, Jacobs PH, Nall L. Tinea versicolor: epidemiologic, clinical, and therapeutic aspects. *J Am Acad Dermatol*. 1991;25(2 Pt 1):300–305. [https://doi.org/10.1016/0190-9622\(91\)70198-b](https://doi.org/10.1016/0190-9622(91)70198-b)
24. Brandi N, Starace M, Alessandrini A, Piraccini BM. Tinea versicolor of the neck as side effect of topical steroids for alopecia areata. *J Dermatolog Treat*. 2019;30(8):757–759. <https://doi.org/10.1080/09546634.2019.1573308>
25. da Fraga CM, de Cássia Birschiner R, Naseri AP, Diniz LM. Influence of systemic corticotherapy on the triggering of pityriasis versicolor. *Mycoses*. 2014;57(9):565–571. <https://doi.org/10.1111/myc.12200>
26. Elmets CA. Management of common superficial fungal infections in patients with AIDS. *J Am Acad Dermatol*. 1994;31(3 Pt 2):S60–S63. [https://doi.org/10.1016/s0190-9622\(08\)81270-4](https://doi.org/10.1016/s0190-9622(08)81270-4)
27. Güleç AT, Demirbilek M, Seçkin D, et al. Superficial fungal infections in 102 renal transplant recipients: a case-control study. *J Am Acad Dermatol*. 2003;49(2):187–192. [https://doi.org/10.1067/s0190-9622\(03\)00861-2](https://doi.org/10.1067/s0190-9622(03)00861-2)
28. Hafez M, el-Shamy S. Genetic susceptibility in pityriasis versicolor. *Dermatologica*. 1985;171(2):86–88. <https://doi.org/10.1159/000249397>
29. Kilinc F, Akbas A, Sener S, Ergin M, Baran P, Metin A. The effect of tinea versicolor on thiol/disulphide homeostasis. *Postepy Dermatol Alergol*. 2018;35(3):299–303. <https://doi.org/10.5114/ada.2018.76227>
30. Kaliyadan F, Ashique KT, Jayasree P. Increased incidence of facial pityriasis versicolor in children during the COVID-19 pandemic—A consequence of mask usage? *Pediatr Dermatol*. 2022;39(5):834–835. <https://doi.org/10.1111/pde.15043>
31. Kutlu Ö, Doğan Z, Ekşioğlu HM, Kekilli M. Relationship between helicobacter pylori infection and pityriasis versicolor: can helicobacter pylori infection be a new etiologic factor for pityriasis versicolor? *Turk J Med Sci*. 2020;50(4):771–775. <https://doi.org/10.3906/sag-1910-48>
32. Levy MS, Polsky D, Davidson A, Strober BE. Tinea versicolor associated with etanercept therapy. *J Am Acad Dermatol*. 2008;58(5 Suppl. 1):S99–S100. <https://doi.org/10.1016/j.jaad.2007.01.023>
33. Mendez-Tovar LJ. Pathogenesis of dermatophytosis and tinea versicolor. *Clin Dermatol*. 2010;28(2):185–189. <https://doi.org/10.1016/j.clindermatol.2009.12.015>
34. Miotto IZ, De Oliveira WRP. Epidermodysplasia verruciformis: report of two patients with autosomal dominant inheritance. *Dermatol Online J*. 2021;27(2):13030/qt53t469nn
35. Renati S, Cukras A, Bigby M. Pityriasis versicolor. *BMJ*. 2015;350:h1394. <https://doi.org/10.1136/bmj.h1394>
36. Schechtman RC, Midgley G, Hay RJ. HIV disease and *Malassezia* yeasts: a quantitative study of patients presenting with seborrhoeic dermatitis. *Br J Dermatol*. 1995;133(5):694–698. <https://doi.org/10.1111/j.1365-2133.1995.tb02740.x>
37. Charles CR, Sire DJ, Johnson BL, Beidler JG. Hypopigmentation in tinea versicolor: a histochemical and electronmicroscopic study. *Int J Dermatol*. 1973;12(1):48–58. <https://doi.org/10.1111/j.1365-4362.1973.tb00212.x>

38. Galadari I, el Komy M, Mousa A, Hashimoto K, Mehregan AH. Tinea versicolor: histologic and ultrastructural investigation of pigmentary changes. *Int J Dermatol*. 1992;31(4):253–256. <https://doi.org/10.1111/j.1365-4362.1992.tb03565.x>
39. Karaoui R, Bou-Resli M, Al-Zaid NS, Mousa A. Tinea versicolor: ultrastructural studies on hypopigmented and hyperpigmented skin. *Dermatologica*. 1981;162(2):69–85. <https://doi.org/10.1159/000250253>
40. Nazzaro-Porro M, Passi S. Identification of tyrosinase inhibitors in cultures of *Pityrosporum*. *J Invest Dermatol*. 1978;71(3):205–208. <https://doi.org/10.1111/1523-1747.ep12547184>
41. Aljabre SH, Alzayir AA, Abdulghani M, Osman OO. Pigmentary changes of tinea versicolor in dark-skinned patients. *Int J Dermatol*. 2001;40(4):273–275. <https://doi.org/10.1046/j.1365-4362.2001.01201.x>
42. Dotz WI, Henrikson DM, Yu GS, Galey CI. Tinea versicolor: a light and electron microscopic study of hyperpigmented skin. *J Am Acad Dermatol*. 1985;12(1 Pt 1):37–44. [https://doi.org/10.1016/s0190-9622\(85\)70006-0](https://doi.org/10.1016/s0190-9622(85)70006-0)
43. Han A, Calcara DA, Stoecker WV, Daly J, Siegel DM, Shell A. Evoked scale sign of tinea versicolor. *Arch Dermatol*. 2009;145(9):1078. <https://doi.org/10.1001/archdermatol.2009.203>
44. Rivard SC. Pityriasis versicolor: avoiding pitfalls in disease diagnosis and therapy. *Mil Med*. 2013;178(8):904–906. <https://doi.org/10.7205/MILMED-D-13-00057>
45. Gupta AK, Batra R, Bluhm R, Faergemann J. Pityriasis versicolor. *Dermatol Clin*. 2003;21(3):413–429, v–vi. [https://doi.org/10.1016/s0733-8635\(03\)00039-1](https://doi.org/10.1016/s0733-8635(03)00039-1)
46. Hellgren L, Vincent J. The incidence of tinea versicolor in central Sweden. *J Med Microbiol*. 1983;16(4):501–502. <https://doi.org/10.1099/00222615-16-4-501>
47. Bélec L, Testa J, Bouree P. Pityriasis versicolor in the Central African Republic: a randomized study of 144 cases. *J Med Vet Mycol*. 1991;29(5):323–329. <https://doi.org/10.1080/02681219180000491>
48. Faergemann J, Fredriksson T. Tinea versicolor with regard to seborrheic dermatitis. An epidemiological investigation. *Arch Dermatol*. 1979;115(8):966–968. <https://doi.org/10.1001/archderm.1979.04010080030017>
49. Ghosh SK, Dey SK, Saha I, Barbhuiya JN, Ghosh A, Roy AK. Pityriasis versicolor: a clinicomycological and epidemiological study from a tertiary care hospital. *Indian J Dermatol*. 2008;53(4):182–185. <https://doi.org/10.4103/0019-5154.44791>
50. He SM, Du WD, Yang S, et al. The genetic epidemiology of tinea versicolor in China. *Mycoses*. 2008;51(1):55–62. <https://doi.org/10.1111/j.1439-0507.2007.01437.x>
51. Jena DK, Sengupta S, Dwari BC, Ram MK. Pityriasis versicolor in the pediatric age group. *Indian J Dermatol Venereol Leprol*. 2005;71(4):259–261. <https://doi.org/10.4103/0378-6323.16618>
52. Karakaş M, Turaç-Biçer A, Ilkit M, Durdu M, Seydaoğlu G. Epidemiology of pityriasis versicolor in Adana, Turkey. *J Dermatol*. 2009;36(7):377–382. <https://doi.org/10.1111/j.1346-8138.2009.00663.x>
53. Leung AKC, Barankin B. Tinea versicolor in a 69-year-old man: an uncommon finding. *Sch J Med Case Rep*. 2015;3(10A):993–994.
54. Rao GS, Kuruvilla M, Kumar P, Vinod V. Clinico-epidermiological studies on tinea versicolor. *Indian J Dermatol Venereol Leprol*. 2002;68(4):208–209.
55. Schmidt A. *Malassezia furfur*: a fungus belonging to the physiological skin flora and its relevance in skin disorders. *Cutis*. 1997;59(1):21–24.
56. Abdollahimajd F, Niknezhad N, Niknejad N, Nikvar M. Infantile hypopigmented pityriasis versicolor: two uncommon cases. *Turk Pediatri Ars*. 2019;54(4):277–280. <https://doi.org/10.14744/TurkPediatriArs.2018.62134>
57. Congly H. Pityriasis versicolor in a 3-month-old boy. *Can Med Assoc J*. 1984;130(7):844–845.
58. Jubert E, Martín-Santiago A, Bernardino M, Bauzá A. Neonatal pityriasis versicolor. *Pediatr Infect Dis J*. 2015;34(3):329–330. <https://doi.org/10.1097/INF.0000000000000568>
59. Nanda A, Kaur S, Bhakoo ON, Kaur I, Vaishnavi C. Pityriasis (tinea) versicolor in infancy. *Pediatr Dermatol*. 1988;5(4):260–262. <https://doi.org/10.1111/j.1525-1470.1988.tb00900.x>
60. Wyre HW Jr, Johnson WT. Neonatal pityriasis versicolor. *Arch Dermatol*. 1981;117(11):752–753. <https://doi.org/10.1001/archderm.117.11.752>
61. Burke RC. Tinea versicolor: susceptibility factors and experimental infection in human beings. *J Invest Dermatol*. 1961;36:389–402. <https://doi.org/10.1038/jid.1961.60>
62. Gupta AK, Kogan N, Batra R. Pityriasis versicolor: a review of pharmacological treatment options. *Expert Opin Pharmacother*. 2005;6(2):165–178. <https://doi.org/10.1517/14656566.6.2.165>
63. Karray M, McKinney WP. Tinea versicolor. In: StatPearls [Internet]. Treasure Island, FL: StatPearls Publishing. <https://www.ncbi.nlm.nih.gov/books/NBK482500/>. Accessed October 13, 2022.
64. Holliday A, Grider D. Images in clinical medicine. Tinea versicolor. *N Engl J Med*. 2016;374(10):e11. <https://doi.org/10.1056/NEJMicm1501201>

65. Tosti A, Villardita S, Fazzini ML. The parasitic colonization of the horny layer in tinea versicolor. *J Invest Dermatol*. 1972;59(3):233–237. <https://doi.org/10.1111/1523-1747.epi2627257>
66. Hattori M, Ogawa H, Takamori K, Gritiyaranson P, Kotarajaras R. De-(hypo)pigmentation mechanisms of the affected area of pityriasis versicolor. *J Dermatol*. 1984;11(1):63–66. <https://doi.org/10.1111/j.1346-8138.1984.tb01442.x>
67. Chebil W, Haouas N, Chaâbane-Banaoues R, et al. Epidemiology of pityriasis versicolor in Tunisia: clinical features and characterization of *Malassezia* species. *J Mycol Med*. 2022;32(2):101246. <https://doi.org/10.1016/j.mycmed.2022.101246>
68. Cohen L, Seminario-Vidal L, Lockey RF. Dermatologic problems commonly seen by the allergist/immunologist. *J Allergy Clin Immunol Pract*. 2020;8(1):102–112. <https://doi.org/10.1016/j.jaip.2019.07.019>
69. Tan C, Zhu WY, Min ZS. Blaschkoid pityriasis versicolor. *Mycoses*. 2010;53(4):366–368. <https://doi.org/10.1111/j.1439-0507.2009.01721.x>
70. Terragni L, Lasagni A, Oriani A, Gelmetti C. Pityriasis versicolor in the pediatric age. *Pediatr Dermatol*. 1991;8(1):9–12. <https://doi.org/10.1111/j.1525-1470.1991.tb00831.x>
71. Glazer SD, Zuger C. Tinea versicolor of the face. *Cutis*. 1980;26(1):87.
72. Pontasch MJ, Kyanko ME, Brodell RT. Tinea versicolor of the face in black children in a temperate region. *Cutis*. 1989;43(1):81–84.
73. Sandhu K, Kanwar AJ. Extensive pityriasis versicolor of the face. *J Dermatol*. 2004;31(3):258–259. <https://doi.org/10.1111/j.1346-8138.2004.tb00670.x>
74. Terragni L, Lasagni A, Oriani A. Pityriasis versicolor of the face. *Mycoses*. 1991;34(7–8):345–347. <https://doi.org/10.1111/j.1439-0507.1991.tb00674.x>
75. Romano C, Feci L, Mancianti F, Fimiani M. Perineal and genital pityriasis versicolor due to *Malassezia globosa*. *J Eur Acad Dermatol Venereol*. 2015;29(9):1857–1858. <https://doi.org/10.1111/jdv.12547>
76. Aljabre SH. Intertriginous lesions in pityriasis versicolor. *J Eur Acad Dermatol Venereol*. 2003;17(6):659–662. <https://doi.org/10.1046/j.1468-3083.2003.00727.x>
77. Aste N, Pau M, Aste N. Pityriasis versicolor on the groin mimicking erythrasma. *Mycoses*. 2004;47(5–6):249–251. <https://doi.org/10.1111/j.1439-0507.2004.00977.x>
78. Cinelli E, Vastarella M, Fabbrocini G, Gallo L. Erythrasmoid pityriasis versicolor with exclusive involvement of the pubis and inguinal region. *Ital J Dermatol Venereol*. 2021;156(Suppl. 1 to No. 6):11–12. <https://doi.org/10.23736/S2784-8671.18.06208-9>
79. Day T, Scurry J. Vulvar pityriasis versicolor in an immunocompetent woman. *J Low Genit Tract Dis*. 2014;18(3):e71–e73. <https://doi.org/10.1097/LGT.0b013e3182a874bb>
80. Greco V, Megna M, Luciano MA, Fabbrocini G. Pityriasis versicolor with uncommon localizations. *G Ital Dermatol Venereol*. 2020;155(6):786–787. <https://doi.org/10.23736/S0392-0488.18.06120-5>
81. Huang WW, Tharp MD. A case of tinea versicolor of the eyelids. *Pediatr Dermatol*. 2013;30(6):e242–e243. <https://doi.org/10.1111/j.1525-1470.2012.01753.x>
82. Khaddar RK, Cherif F, Ben Hadid R, Mokni M, Ben Osman A. Penile shaft involvement in pityriasis versicolor. *Acta Dermatovenerol Alp Pannonica Adriat*. 2008;17(2):86–89.
83. Nevas J. Tinea versicolor: understanding effective treatment options. *Nurse Pract*. 2012;37(1):11–13. <https://doi.org/10.1097/01.NPR.0000409912.87769.f0>
84. Ryu HW, Cho JW, Lee KS. Pityriasis versicolor on penile shaft in a renal transplant recipient. *Ann Dermatol*. 2012;24(3):345–347. <https://doi.org/10.5021/ad.2012.24.3.345>
85. Sárdy M, Korting HC, Ruzicka T, Wolff H. Bilateral areolar and periareolar pityriasis versicolor. *J Dtsch Dermatol Ges*. 2010;8(8):617–618. <https://doi.org/10.1111/j.1610-0387.2010.07348.x>
86. Smith BL, Koestenblatt EK, Weinberg JM. Areolar and periareolar pityriasis versicolor. *J Eur Acad Dermatol Venereol*. 2004;18(6):740–741. <https://doi.org/10.1111/j.1468-3083.2004.01040.x>
87. Gupta AK, Foley KA. Antifungal treatment for pityriasis versicolor. *J Fungi (Basel)*. 2015;1(1):13–29. <https://doi.org/10.3390/jof1010013>
88. Hudacek KD, Haque MS, Hochberg AL, Cusack CA, Chung CL. An unusual variant of confluent and reticulated papillomatosis masquerading as tinea versicolor. *Arch Dermatol*. 2012;148(4):505–508. <https://doi.org/10.1001/archdermatol.2011.2812>
89. Shi VS, Lio PA. Diagnosis of pityriasis versicolor in paediatrics: the evoked scale sign. *Arch Dis Child*. 2011;96(4):392–393. <https://doi.org/10.1136/adc.2010.200238>
90. McNally B, McGraw T. Picture this... Tinea versicolor. *J Spec Oper Med*. 2010;10(1):107–110.
91. Bonifaz A, Gómez-Daza F, Paredes V, Ponce RM. Tinea versicolor, tinea nigra, white piedra, and black piedra. *Clin Dermatol*. 2010;28(2):140–145. <https://doi.org/10.1016/j.clindermatol.2009.12.004>

92. Ferry M, Shedlofsky L, Newman A, Mengesha Y, Blumetti B. Tinea in versicolor: a rare distribution of a common eruption. *Cureus*. 2020;12(1):e6689. <https://doi.org/10.7759/cureus.6689>
93. Rudolph RI, Holzwanger JM. Letter: inverse tinea versicolor. *Arch Dermatol*. 1975;111(9):1213. <https://doi.org/10.1001/archderm.111.9.1213c>
94. Varada S, Dabade T, Loo DS. Uncommon presentations of tinea versicolor. *Dermatol Pract Concept*. 2014;4(3):93–96. <https://doi.org/10.5826/dpc.0403a21>
95. Haiduk J, Treudler R, Ziemer M. Atrophying tinea versicolor with epidermal atrophy. *J Dtsch Dermatol Ges*. 2016;14(7):740–743. <https://doi.org/10.1111/ddg.12894>
96. Moon SY, Lee WJ, Lee SJ, Kim DW, Jang YH. Pityriasis versicolor atrophicans: is it true atrophy or pseudoatrophy? *J Cutan Pathol*. 2016;43(2):187–189. <https://doi.org/10.1111/cup.12596>
97. Romano C, Maritati E, Ghilardi A, Miracco C, Mancianti F. A case of pityriasis versicolor atrophicans. *Mycoses*. 2005;48(6):439–441. <https://doi.org/10.1111/j.1439-0507.2005.01160.x>
98. Tellechea O, Cravo M, Brinca A, Robalo-Cordeiro M. Pityriasis versicolor atrophicans. *Eur J Dermatol*. 2012;22(2):287–288. <https://doi.org/10.1684/ejd.2012.1661>
99. Allegue F, Fachal C, González-Vilas D, Zulaica A. Atrophying pityriasis versicolor. *Actas Dermosifiliogr*. 2018;109(5):455–457. <https://doi.org/10.1016/j.ad.2017.08.013>
100. Cullingham K, Hull PR. Atrophying pityriasis versicolor. *CMAJ*. 2014;186(10):776. <https://doi.org/10.1503/cmaj.131846>
101. Crowson AN, Magro CM. Atrophying tinea versicolor: a clinical and histological study of 12 patients. *Int J Dermatol*. 2003;42(12):928–932. <https://doi.org/10.1111/j.1365-4632.2003.02110.x>
102. Levy JM, Magro C. Atrophying pityriasis versicolor as an idiosyncratic T cell-mediated response to Malassezia: a case series. *J Am Acad Dermatol*. 2017;76(4):730–735. <https://doi.org/10.1016/j.jaad.2016.08.062>
103. Marinello E, Piaserico S, Alaibac M. Atrophic pityriasis versicolor occurring in a patient with Sjögren's syndrome. *BMJ Case Rep*. 2017;2017:bcr2016218108. <https://doi.org/10.1136/bcr-2016-218108>
104. Yang YS, Shin MK, Haw CR. Atrophying pityriasis versicolor: is this a new variant of pityriasis versicolor? *Ann Dermatol*. 2010;22(4):456–469. <https://doi.org/10.5021/ad.2010.22.4.456>
105. Baz K, Kokturk A, Kaya TI, Ikizoglu G, Yazici AC, Bocekli E. Confetti-like pityriasis versicolor. *J Eur Acad Dermatol Venereol*. 2004;18(2):240–241. <https://doi.org/10.1111/j.1468-3083.2004.00871.x>
106. Nabatian AS, Millett CR, Heymann WR. What is your diagnosis? Folliculocentric tinea versicolor. *Cutis*. 2012;90(3):113, 117–118.
107. Hudson A, Carroll B, Kim SJ. Folliculocentric tinea versicolor. *Dermatol Online J*. 2017;23(2). <https://doi.org/10.5070/D3232033966>
108. VanDersarl JV, Arnold WL. "Acid skin" in black patients. *Arch Dermatol*. 1983;119(8):627. <https://doi.org/10.1001/archderm.119.8.627b>
109. Al-Refu K. Dermoscopy is a new diagnostic tool in diagnosis of common hypopigmented macular disease: a descriptive study. *Dermatol Reports*. 2018;11(1):7916. <https://doi.org/10.4081/dr.2018.7916>
110. Kapadia F, Kharkar V, Vishwanath T. Dermoscopy to the rescue in an annular enigma: a rare case of annular pityriasis versicolor presenting in an unusual location. *Dermatol Pract Concept*. 2022;12(2):e2022057. <https://doi.org/10.5826/dpc.1202a57>
111. Kaur I, Jakhar D, Singal A. Dermoscopy in the evaluation of pityriasis versicolor: a cross sectional study. *Indian Dermatol Online J*. 2019;10(6):682–685. https://doi.org/10.4103/idoj.IDOJ_502_18
112. Mathur M, Acharya P, Karki A, Kc N, Shah J. Dermoscopic pattern of pityriasis versicolor. *Clin Cosmet Investig Dermatol*. 2019;12:303–309. <https://doi.org/10.2147/CCID.S195166>
113. Thomas N, Malakar S. Dermoscopy: an easy way to solve the diagnostic puzzle in pityriasis versicolor. *Indian J Dermatol Venereol Leprol*. 2019;85(6):664–665. https://doi.org/10.4103/ijdv.IJDVL_816_16
114. Zhou H, Tang XH, De Han J, Chen MK. Dermoscopy as an ancillary tool for the diagnosis of pityriasis versicolor. *J Am Acad Dermatol*. 2015;73(6):e205–e206. <https://doi.org/10.1016/j.jaad.2015.08.058>
115. Lim SL, Lim CS. New contrast stain for the rapid diagnosis of pityriasis versicolor. *Arch Dermatol*. 2008;144(8):1058–1059. <https://doi.org/10.1001/archderm.144.8.1058>
116. Lodha N, Poojary SA. A novel contrast stain for the rapid diagnosis of pityriasis versicolor: a comparison of Chicago Sky Blue 6B Stain, potassium hydroxide mount and culture. *Indian J Dermatol*. 2015;60(4):340–344. <https://doi.org/10.4103/0019-5154.160476>
117. Day W, Prodanovic E. Borderline lepromatous leprosy masking as tinea versicolor. *Int J Dermatol*. 2019;58(6):e125–e126. <https://doi.org/10.1111/ijd.14439>
118. Jadotte YT, Janniger CK. Pityriasis alba revisited: perspectives on an enigmatic disorder of childhood. *Cutis*. 2011;87(2):66–72.

119. Leung AK, Robson WL. Tuberous sclerosis complex: a review. *J Pediatr Health Care*. 2007;21(2):108–114. <https://doi.org/10.1016/j.pedhc.2006.05.004>
120. Leung AKC, Lam JM, Leong KF, Hon KL. Vitiligo: an updated narrative review. *Curr Pediatr Rev*. 2021;17(2):76–91. <https://doi.org/10.2174/1573396316666201210125858>
121. Massone C, Cavalchini A, Clapasson A, Nunzi E. Hypopigmented macules: leprosy, atopy or pityriasis versicolor? *G Ital Dermatol Venereol*. 2010;145(6):779–782.
122. Qualia CM, Brown MR, Leung AK, et al. Index of suspicion. *Pediatr Rev*. 2007;28(5):193–198. <https://doi.org/10.1542/pir.28-5-193>
123. Saleem MD, Oussedik E, Picardo M, Schoch JJ. Acquired disorders with hypopigmentation: a clinical approach to diagnosis and treatment. *J Am Acad Dermatol*. 2019;80(5):1233–1250.e10. <https://doi.org/10.1016/j.jaad.2018.07.070>
124. Yang S, Makredes M, O'Donnell P, Levin NA. A case of Hansen disease presenting as tinea versicolor. *Dermatol Online J*. 2013;19(4):18176. <https://doi.org/10.5070/D365H88318>
125. Aste N, Pau M, Aste N, Biggio P. Case report. Pityriasis versicolor mimicking pityriasis rotunda. *Mycoses*. 2002;45(3–4):126–128. <https://doi.org/10.1046/j.1439-0507.2002.00735.x>
126. Berry M, Khachemoune A. Extensive tinea versicolor mimicking Pityriasis rubra pilaris. *J Drugs Dermatol*. 2009;8(5):490–491.
127. Bossini B, Mazzolai M, Berti I, Barbi E. Hyperpigmented pityriasis versicolor misdiagnosed as acanthosis nigricans. *Arch Dis Child*. 2022;107(1):92. <https://doi.org/10.1136/archdischild-2021-322030>
128. Darling MJ, Lambiase MC, Young RJ. Tinea versicolor mimicking pityriasis rubra pilaris. *Cutis*. 2005;75(5):265–267.
129. Ena P, Siddi GM. Pityriasis versicolor resembling pityriasis rotunda. *J Eur Acad Dermatol Venereol*. 2002;16(1):85–87. https://doi.org/10.1046/j.1468-3083.2002.373_5.x
130. Forouzan P, Cohen PR. Erythrasma revisited: diagnosis, differential diagnoses, and comprehensive review of treatment. *Cureus*. 2020;12(9):e10733. <https://doi.org/10.7759/cureus.10733>
131. Leung AKC, Barankin B, Lam JM. Terra firma-forme dermatosis. *J Pediatr*. 2018;195:302–303. <https://doi.org/10.1016/j.jpeds.2017.12.014>
132. Leung AKC, Leong KF, Lam JM. Tinea imbricata. *J Pediatr*. 2018;200:285–285.e1. <https://doi.org/10.1016/j.jpeds.2018.04.012>
133. Leung AKC, Leong KF, Lam JM. Tinea imbricata: an overview. *Curr Pediatr Rev*. 2019;15(3):170–174. <https://doi.org/10.2174/1573396315666190207151941>
134. Leung AK, Lam JM, Leong KF, Hon KL. Tinea corporis: an updated review. *Drugs Context*. 2020;9:2020–5–6. <https://doi.org/10.7573/dic.2020-5-6>
135. Leung AKC, Lam JM, Leong KF, Hon KL. Vitiligo: an updated narrative review. *Curr Pediatr Rev*. 2021;17(2):76–91. <https://doi.org/10.2174/1573396316666201210125858>
136. Leung AKC, Lam JM, Leong KF, Hon KL. Pityriasis rosea: an updated review. *Curr Pediatr Rev*. 2021;17(3):201–211. <https://doi.org/10.2174/1573396316666200923161330>
137. Plensdorf S, Livieratos M, Dada N. Pigmentation disorders: diagnosis and management. *Am Fam Physician*. 2017;96(12):797–804.
138. Zhang B, Xing H, Rui H, Song L, Ma L. Epidermodysplasia verruciformis mimicking pityriasis versicolor. *Pediatr Investig*. 2021;5(4):325–326. <https://doi.org/10.1002/ped4.12288>
139. Mayser P, Rieche I. Rapid reversal of hyperpigmentation in pityriasis versicolor upon short-term topical cycloserine application. *Mycoses*. 2009;52(6):541–543. <https://doi.org/10.1111/j.1439-0507.2009.01784.x>
140. Mostafa WZ, Assaf MI, Ameen IA, El Safoury OS, Al Sulh SA. Hair loss in pityriasis versicolor lesions: a descriptive clinicopathological study. *J Am Acad Dermatol*. 2013;69(1):e19–e23. <https://doi.org/10.1016/j.jaad.2012.03.004>
141. Gupta AK, Lyons DC. Pityriasis versicolor: an update on pharmacological treatment options. *Expert Opin Pharmacother*. 2014;15(12):1707–1713. <https://doi.org/10.1517/14656566.2014.931373>
142. Gupta AK, Lane D, Paquet M. Systematic review of systemic treatments for tinea versicolor and evidence-based dosing regimen recommendations. *J Cutan Med Surg*. 2014;18(2):79–90. <https://doi.org/10.2310/7750.2013.13062>
143. Pantazidou A, Tebruegge M. Recurrent tinea versicolor: treatment with itraconazole or fluconazole? *Arch Dis Child*. 2007;92(11):1040–1042. <https://doi.org/10.1136/adc.2007.124958>
144. Dyląg M, Leniak E, Gnat S, Szepietowski JC, Kozubowski L. A case of anti-pityriasis versicolor therapy that preserves healthy mycobiome. *BMC Dermatol*. 2020;20:9. <https://doi.org/10.1186/s12895-020-00106-x>
145. Framil VM, Melhem MS, Szeszs MW, Zaitz C. New aspects in the clinical course of pityriasis versicolor. *An Bras Dermatol*. 2011;86(6):1135–1140. <https://doi.org/10.1590/s0365-05962011000600011>
146. Faergemann J. Pityrosporum species as a cause of allergy and infection. *Allergy*. 1999;54(5):413–419. <https://doi.org/10.1034/j.1398-9995.1999.00089.x>

147. Hu SW, Bigby M. Pityriasis versicolor: a systematic review of interventions. *Arch Dermatol*. 2010;146(10):1132–1140. <https://doi.org/10.1001/archdermatol.2010.259>
148. Helou J, Obeid G, Moutran R, Maatouk I. Pityriasis versicolor: a case of resistance to treatment. *Int J Dermatol*. 2014;53(2):e114–e116. <https://doi.org/10.1111/j.1365-4632.2012.05689.x>
149. Alchorne MM, Paschoalick RC, Forjaz MH. Comparative study of tioconazole and clotrimazole in the treatment of tinea versicolor. *Clin Ther*. 1987;9(4):360–367.
150. Aste N, Pau M, Cordaro CI, Biggio P. Double-blind study with fenticonazole or bifonazole lotions in pityriasis versicolor. *Int J Clin Pharmacol Res*. 1988;8(4):271–273.
151. Balwada RP, Jain VK, Dayal S. A double-blind comparison of 2% ketoconazole and 1% clotrimazole in the treatment of pityriasis versicolor. *Indian J Dermatol Venereol Leprol*. 1996;62(5):298–300.
152. Cantrell WC, Elewski BE. Can pityriasis versicolor be treated with 2% ketoconazole foam? *J Drugs Dermatol*. 2014;13(7):855–859.
153. Clayton R, Du Vivier A, Savage M. Double-blind trial of 1% clotrimazole cream and Whitfield ointment in the treatment of pityriasis versicolor. *Arch Dermatol*. 1977;113(6):849–850. <https://doi.org/10.1001/archderm.1977.01640060145029>
154. del Palacio Hernanz A, López Gómez S, Iglesias Diez L. Short course bifonazole therapy in pityriasis versicolor. *Clin Exp Dermatol*. 1987;12(4):270–272. <https://doi.org/10.1111/j.1365-2230.1987.tb01917.x>
155. Di Fonzo EM, Martini P, Mazzatenta C, Lotti L, Alvino S. Comparative efficacy and tolerability of Ketomousse (ketoconazole foam 1%) and ketoconazole cream 2% in the treatment of pityriasis versicolor: results of a prospective, multicentre, randomised study. *Mycoses*. 2008;51(6):532–535. <https://doi.org/10.1111/j.1439-0507.2008.01508.x>
156. El-Housiny S, Shams Eldeen MA, El-Attar YA, et al. Fluconazole-loaded solid lipid nanoparticles topical gel for treatment of pityriasis versicolor: formulation and clinical study. *Drug Deliv*. 2018;25(1):78–90. <https://doi.org/10.1080/10717544.2017.1413444>
157. Gobbato AA, Babadópulos T, Gobbato CA, Ilha Jde O, Gagliano-Jucá T, De Nucci G. A randomized double-blind, non-inferiority Phase II trial, comparing dapaconazole tosylate 2% cream with ketoconazole 2% cream in the treatment of pityriasis versicolor. *Expert Opin Investig Drugs*. 2015;24(11):1399–1407. <https://doi.org/10.1517/13543784.2015.1083009>
158. Hay RJ, Adriaans B, Midgley G, English JS, Zachary CB. A single application of bifonazole 1% lotion in pityriasis versicolor. *Clin Exp Dermatol*. 1987;12(4):315. <https://doi.org/10.1111/j.1365-2230.1987.tb01932.x>
159. Haroon TS, Tareen MI, Hafiz A, Rizwana. An open study of tioconazole 1% dermal cream in patients with pityriasis versicolor. *J Pak Med Assoc*. 1984;34(12):361–362.
160. Rigopoulos D, Katsambas A, Antoniou C, Polydorou D, Vlachou M, Stratigos J. Tinea versicolor treated with fluconazole shampoo. *Int J Dermatol*. 1992;31(9):664–665. <https://doi.org/10.1111/j.1365-4362.1992.tb03992.x>
161. Sarkar S, Sengupta D, Basak S, Damji SA, Shukla DK, Anurag D. Comparative assessment of the efficacy of topical ketoconazole and topical luliconazole in cases of pityriasis versicolor at a tertiary care hospital in eastern India: a prospective, open, randomized controlled trial. *Indian Dermatol Online J*. 2016;7(4):335–336. <https://doi.org/10.4103/2229-5178.185471>
162. Savin RC, Horwitz SN. Double-blind comparison of 2% ketoconazole cream and placebo in the treatment of tinea versicolor. *J Am Acad Dermatol*. 1986;15(3):500–503. [https://doi.org/10.1016/s0190-9622\(86\)70200-4](https://doi.org/10.1016/s0190-9622(86)70200-4)
163. Sharma J, Kaushal J, Aggarwal K. A comparative study of efficacy and safety of eberconazole versus terbinafine in patients of tinea versicolor. *Indian J Dermatol*. 2018;63(1):53–56. https://doi.org/10.4103/ijid.IJD_126_17
164. Spiekermann PH, Young MD. Clinical evaluation of clotrimazole. A broad-spectrum antifungal agent. *Arch Dermatol*. 1976;112(3):350–352. <https://doi.org/10.1001/archderm.112.3.350>
165. Vicik GJ, Mendiones M, Quinones CA, Thorne EG. A new treatment for tinea versicolor using econazole nitrate 1.0 percent cream once a day. *Cutis*. 1984;33(6):570–571.
166. Choi FD, Juhasz MLW, Atanaskova Mesinkovska N. Topical ketoconazole: a systematic review of current dermatological applications and future developments. *J Dermatolog Treat*. 2019;30(8):760–771. <https://doi.org/10.1080/09546634.2019.1573309>
167. Elewski BE. Mechanisms of action of systemic antifungal agents. *J Am Acad Dermatol*. 1993;28(5 Pt 1):S28–S34. [https://doi.org/10.1016/s0190-9622\(09\)80305-8](https://doi.org/10.1016/s0190-9622(09)80305-8)
168. Beetens JR, Loots W, Somers Y, Coene MC, De Clerck F. Ketoconazole inhibits the biosynthesis of leukotrienes in vitro and in vivo. *Biochem Pharmacol*. 1986;35(6):883–891. [https://doi.org/10.1016/0006-2952\(86\)90072-9](https://doi.org/10.1016/0006-2952(86)90072-9)
169. De Pedrini P, Rapisarda R, Spanò G. The effect of ketoconazole on sebum secretion in patients suffering from acne and seborrhoea. *Int J Tissue React*. 1988;10(2):111–113.

170. Van Cutsem J, Van Gerven F, Cauwenbergh G, Odds F, Janssen PA. The antiinflammatory effects of ketoconazole. A comparative study with hydrocortisone acetate in a model using living and killed *Staphylococcus aureus* on the skin of guinea-pigs. *J Am Acad Dermatol*. 1991;25(2 Pt 1):257–261. [https://doi.org/10.1016/0190-9622\(91\)70192-5](https://doi.org/10.1016/0190-9622(91)70192-5)
171. Bakr E, Abdo H, Abd-Elaziz H, Abd-Elrazek H, Amer M. Adapalene gel 0.1% vs ketoconazole cream 2% and their combination in treatment of pityriasis versicolor: a randomized clinical study. *Dermatol Ther*. 2020;33(3):e13319. <https://doi.org/10.1111/dth.13319>
172. Shi TW, Zhang JA, Tang YB, Yu HX, Li ZG, Yu JB. A randomized controlled trial of combination treatment with ketoconazole 2% cream and adapalene 0.1% gel in pityriasis versicolor. *J Dermatolog Treat*. 2015;26(2):143–146. <https://doi.org/10.3109/09546634.2014.921661>
173. Bseiso EA, Nasr M, Sammour O, Abd El Gawad NA. Recent advances in topical formulation carriers of antifungal agents. *Indian J Dermatol Venereol Leprol*. 2015;81(5):457–463. <https://doi.org/10.4103/0378-6323.162328>
174. Deng P, Teng F, Zhou F, et al. Y-shaped methoxy poly (ethylene glycol)-block-poly (epsilon-caprolactone)-based micelles for skin delivery of ketoconazole: in vitro study and in vivo evaluation. *Mater Sci Eng C Mater Biol Appl*. 2017;78:296–304. <https://doi.org/10.1016/j.msec.2017.04.089>
175. Patel MR, Patel RB, Parikh JR, Solanki AB, Patel BG. Investigating effect of microemulsion components: in vitro permeation of ketoconazole. *Pharm Dev Technol*. 2011;16(3):250–258. <https://doi.org/10.3109/10837451003610845>
176. Souto EB, Müller RH. SLN and NLC for topical delivery of ketoconazole. *J Microencapsul*. 2005;22(5):501–510. <https://doi.org/10.1080/02652040500162436>
177. Lamie C, Elmowafy E, Ragaie MH, Attia DA, Mortada ND. Assessment of antifungal efficacy of itraconazole loaded aspasomal cream: comparative clinical study. *Drug Deliv*. 2022;29(1):1345–1357. <https://doi.org/10.1080/10717544.2022.2067601>
178. Aste N, Pau M, Pinna AL, Colombo MD, Biggio P. Clinical efficacy and tolerability of terbinafine in patients with pityriasis versicolor. *Mycoses*. 1991;34(7–8):353–357. <https://doi.org/10.1111/j.1439-0507.1991.tb00676.x>
179. Faergemann J, Hersle K, Nordin P. Pityriasis versicolor: clinical experience with Lamisil cream and Lamisil DermGel. *Dermatology*. 1997;194(Suppl. 1):19–21. <https://doi.org/10.1159/000246178>
180. Savin R, Eisen D, Fradin MS, Lebwohl M. Tinea versicolor treated with terbinafine 1% solution. *Int J Dermatol*. 1999;38(11):863–865. <https://doi.org/10.1046/j.1365-4362.1999.00730.x>
181. Vermeer BJ, Staats CC. The efficacy of a topical application of terbinafine 1% solution in subjects with pityriasis versicolor: a placebo-controlled study. *Dermatology*. 1997;194(Suppl. 1):22–24. <https://doi.org/10.1159/000246179>
182. Rad F, Aala F, Reshadmanesh N, Yaghmaie R. Randomized comparative clinical trial of *Artemisia sieberi* 5% lotion and clotrimazole 1% lotion for the treatment of pityriasis versicolor. *Indian J Dermatol*. 2008;53(3):115–118. <https://doi.org/10.4103/0019-5154.43209>
183. Chopra V, Jain VK. Comparative study of topical terbinafine and topical ketoconazole in pityriasis versicolor. *Indian J Dermatol Venereol Leprol*. 2000;66(6):299–300.
184. Del Rosso JQ, Kircik LH. Optimizing topical antifungal therapy for superficial cutaneous fungal infections: focus on topical naftifine for cutaneous dermatophytosis. *J Drugs Dermatol*. 2013;12(Suppl. 11):s165–s171.
185. Albanese G, Giorgetti P, Santagostino L, Di Cintio R, Colombo MD. [Evaluation of the efficacy of a new antimycotic molecule for topical use: naftifine]. *G Ital Dermatol Venereol*. 1989;124(5):XXXIII–XXXVII.
186. Gold MH, Bridges T, Avakian E, et al. An open-label study of naftifine hydrochloride 1% gel in the treatment of tinea versicolor. *Skinmed*. 2011;9(5):283–286.
187. Hira SK, Abraham MS, Mwinga A, Kamanga J, Schmidt C. Naftifine solution (1%) in the treatment of pityriasis versicolor in Zambia. *Mykosen*. 1986;29(8):378–381.
188. Gupta AK. Butenafine: an update of its use in superficial mycoses. *Skin Therapy Lett*. 2002;7(7):1–2,5.
189. Abdul Bari MA. Comparison of superficial mycosis treatment using Butenafine and Bifonazole nitrate clinical efficacy. *Glob J Health Sci*. 2012;5(1):150–154. <https://doi.org/10.5539/gjhs.v5n1p150>
190. Singal A. Butenafine and superficial mycoses: current status. *Expert Opin Drug Metab Toxicol*. 2008;4(7):999–1005. <https://doi.org/10.1517/17425255.4.7.999>
191. No authors listed. Treatment of tinea versicolor with a new antifungal agent, ciclopirox olamine cream 1%. *Clin Ther*. 1985;7(5):574–583.
192. del Palacio-Hernanz A, Guarro-Artigas J, Figueras-Salvat MJ, Esteban-Moreno J, Lopez-Gomez S. Changes in fungal ultrastructure after short-course ciclopiroxolamine therapy in pityriasis versicolor. *Clin Exp Dermatol*. 1990;15(2):95–100. <https://doi.org/10.1111/j.1365-2230.1990.tb02040.x>
193. Kudriavskaja VM, Rudenko AV, Pyrig LA. [Drug sensitivity of *Candida* in patients with kidney diseases receiving immunosuppressive therapy]. *Antibiot Khimioter*. 1989;34(10):769–773.

194. Gupta AK, Daigle D, Foley KA. Drug safety assessment of oral formulations of ketoconazole. *Expert Opin Drug Saf*. 2015;14(2):325–334. <https://doi.org/10.1517/14740338.2015.983071>
195. Hersle K. Selenium sulphide treatment of tinea versicolor. *Acta Derm Venereol*. 1971;51(6):476–478.
196. Sánchez JL, Torres VM. Double-blind efficacy study of selenium sulfide in tinea versicolor. *J Am Acad Dermatol*. 1984 Aug;11(2 Pt 1):235–238. [https://doi.org/10.1016/s0190-9622\(84\)70155-1](https://doi.org/10.1016/s0190-9622(84)70155-1)
197. Sánchez JL, Torres VM. Selenium sulfide in tinea versicolor: blood and urine levels. *J Am Acad Dermatol*. 1984;11(2 Pt 1):238–241. [https://doi.org/10.1016/s0190-9622\(84\)70156-3](https://doi.org/10.1016/s0190-9622(84)70156-3)
198. Chu AC. Comparative clinical trial of bifonazole solution versus selenium sulphide shampoo in the treatment of pityriasis versicolor. *Dermatologica*. 1984;169(Suppl. 1):81–86. <https://doi.org/10.1159/000249644>
199. Katsambas A, Rigopoulos D, Antoniou C, Zachari A, Fragouli E, Stratigos J. Econazole 1% shampoo versus selenium in the treatment of tinea versicolor: a single-blind randomized clinical study. *Int J Dermatol*. 1996;35(9):667–668. <https://doi.org/10.1111/j.1365-4362.1996.tb03700.x>
200. Faergemann J, Fredriksson T. An open trial of the effect of a zinc pyrithione shampoo in tinea versicolor. *Cutis*. 1980;25(6):667, 669.
201. Fredriksson T, Faergemann J. Double-blind comparison of a zinc pyrithione shampoo and its shampoo base in the treatment of tinea versicolor. *Cutis*. 1983;31(4):436–437.
202. Faergemann J, Fredriksson T. Propylene glycol in the treatment of tinea versicolor. *Acta Derm Venereol*. 1980;60(1):92–93.
203. Clayton YM, Connor BL. Comparison of clotrimazole cream, Whitfield's ointment and Nystatin ointment for the topical treatment of ringworm infections, pityriasis versicolor, erythrasma and candidiasis. *Br J Dermatol*. 1973;89(3):297–303. <https://doi.org/10.1111/j.1365-2133.1973.tb02978.x>
204. Bamford JT. Editorial: tinea versicolor treatment. *Arch Dermatol*. 1974;110(6):956. <https://doi.org/10.1001/archderm.1974.01630120088025>
205. Bamford JT. Treatment of tinea versicolor with sulfur-salicylic shampoo. *J Am Acad Dermatol*. 1983;8(2):211–213. [https://doi.org/10.1016/s0190-9622\(83\)70026-5](https://doi.org/10.1016/s0190-9622(83)70026-5)
206. Faergemann J, Fredriksson T. Antimycotic activity of propane-1,2-diol (propylene glycol). *Sabouraudia*. 1980;18(3):163–166. <https://doi.org/10.1080/00362178085380301>
207. Kligman AM, Leyden JJ, Stewart R. New uses for benzoyl peroxide: a broad-spectrum antimicrobial agent. *Int J Dermatol*. 1977;16(5):413–417. <https://doi.org/10.1111/j.1365-4362.1977.tb00769.x>
208. Prestia AE. Topical benzoyl peroxide for the treatment of tinea versicolor. *J Am Acad Dermatol*. 1983;9(2):277–278. [https://doi.org/10.1016/s0190-9622\(83\)80152-2](https://doi.org/10.1016/s0190-9622(83)80152-2)
209. Nagpal VB, Jain VK, Aggarwal K. Comparative study of oral and topical ketoconazole therapy in pityriasis versicolor. *Indian J Dermatol Venereol Leprol*. 2003;69(4):287–288.
210. Hickman JG. A double-blind, randomized, placebo-controlled evaluation of short-term treatment with oral itraconazole in patients with tinea versicolor. *J Am Acad Dermatol*. 1996;34(5 Pt 1):785–787. [https://doi.org/10.1016/s0190-9622\(96\)90014-6](https://doi.org/10.1016/s0190-9622(96)90014-6)
211. Karakaş M, Durdu M, Memişoğlu HR. Oral fluconazole in the treatment of tinea versicolor. *J Dermatol*. 2005;32(1):19–21. <https://doi.org/10.1111/j.1346-8138.2005.tb00707.x>
212. Aksoy B. Itraconazole-induced thrombocytopenia. *Cutan Ocul Toxicol*. 2017;36(3):305–306. <https://doi.org/10.1080/15569527.2016.1257995>
213. Lyman CA, Walsh TJ. Systemically administered antifungal agents. A review of their clinical pharmacology and therapeutic applications. *Drugs*. 1992;44(1):9–35. <https://doi.org/10.2165/00003495-199244010-00002>
214. Wahab MA, Kamal SB, Shahin MR, et al. Efficacy of itraconazole in the prevention of recurrence of tinea versicolor: a three year follow up. *Mymensingh Med J*. 2020;29(2):351–356.
215. Wishart JM. The influence of food on the pharmacokinetics of itraconazole in patients with superficial fungal infection. *J Am Acad Dermatol*. 1987;17(2 Pt 1):220–223. [https://doi.org/10.1016/s0190-9622\(87\)70194-7](https://doi.org/10.1016/s0190-9622(87)70194-7)
216. Faergemann J, Gupta AK, Al Mofadi A, Abanami A, Shareaah AA, Marynissen G. Efficacy of itraconazole in the prophylactic treatment of pityriasis (tinea) versicolor. *Arch Dermatol*. 2002;138(1):69–73. <https://doi.org/10.1001/archderm.138.1.69>
217. Cam VT, Van TN, Hau KT, et al. Efficacy of azole antifungal in treatment of pityriasis versicolor. *Open Access Maced J Med Sci*. 2019;7(2):272–274. <https://doi.org/10.3889/oamjms.2019.092>
218. Muhammad N, Kamal M, Islam T, Islam N, Shafiquzzaman M. A study to evaluate the efficacy and safety of oral fluconazole in the treatment of tinea versicolor. *Mymensingh Med J*. 2009;18(1):31–35.
219. Partap R, Kaur I, Chakrabarti A, Kumar B. Single-dose fluconazole versus itraconazole in pityriasis versicolor. *Dermatology*. 2004;208(1):55–59. <https://doi.org/10.1159/000075047>

220. García Rodríguez LA, Duque A, Castellsague J, Pérez-Gutthann S, Stricker BH. A cohort study on the risk of acute liver injury among users of ketoconazole and other antifungal drugs. *Br J Clin Pharmacol*. 1999;48(6):847–852. <https://doi.org/10.1046/j.1365-2125.1999.00095.x>
221. Yan JY, Nie XL, Tao QM, Zhan SY, Zhang YD. Ketoconazole associated hepatotoxicity: a systematic review and meta-analysis. *Biomed Environ Sci*. 2013;26(7):605–610. <https://doi.org/10.3967/0895-3988.2013.07.013>
222. Alberdi E, Gómez C. Successful treatment of Pityriasis Versicolor by photodynamic therapy mediated by methylene blue. *Photodermatol Photoimmunol Photomed*. 2020;36(4):308–312. <https://doi.org/10.1111/phpp.12555>
223. Balevi A, Üstüner P, Kakşi SA, Özdemir M. Narrow-band UV-B phototherapy: an effective and reliable treatment alternative for extensive and recurrent pityriasis versicolor. *J Dermatolog Treat*. 2018;29(3):252–255. <https://doi.org/10.1080/09546634.2017.1364690>
224. Khattab FM, Omran FH. 308-nm excimer laser: a hopeful and optional therapy for pityriasis versicolor. *J Dermatolog Treat*. 2021;32(7):795–799. <https://doi.org/10.1080/09546634.2020.1713972>
225. Kim YJ, Kim YC. Successful treatment of pityriasis versicolor with 5-aminolevulinic acid photodynamic therapy. *Arch Dermatol*. 2007;143(9):1218–1220. <https://doi.org/10.1001/archderm.143.9.1218>
226. Cherniack EP. Bugs as drugs, Part I: insects: the “new” alternative medicine for the 21st century? *Altern Med Rev*. 2010;15(2):124–135.
227. Carmo ES, Pereira Fde O, Cavalcante NM, Gayoso CW, Lima Ede O. Treatment of pityriasis versicolor with topical application of essential oil of *Cymbopogon citratus* (DC) Stapf – therapeutic pilot study. *An Bras Dermatol*. 2013;88(3):381–385. <https://doi.org/10.1590/abd1806-4841.20131800>
228. Mirzaii M, Yaeghoobi M, Afzali M, Amirkhalili N, Mahmoodi M, Sajirani EB. Antifungal activities of quince seed mucilage hydrogel decorated with essential oils of *Nigella sativa*, *Citrus sinensis* and *Cinnamon verum*. *Iran J Microbiol*. 2021;13(3):352–359. <https://doi.org/10.18502/ijm.v13i3.6398>
229. Lone AH, Ahmad T, Anwar M, Sofi G. Clinical efficacy and safety of a pharmacopial polyherbal Unani formulation in pityriasis versicolor: a comparative randomized single-blind study. *J Altern Complement Med*. 2012;18(10):978–982. <https://doi.org/10.1089/acm.2011.0520>
230. Kagisha V, Djang'eing'a RM, Muganga R, et al. *Pentas longiflora Oliv.* (Rubiaceae), a plant used in the treatment of pityriasis versicolor in Rwanda: chemical composition and standardization of leaves and roots. *Fitoterapia*. 2021;153:104974. <https://doi.org/10.1016/j.fitote.2021.104974>
231. Sherifat KO, Itohan AM, Adeola SO, Adeola KM, Aderemi OL. Antifungal activity of *Acalypha wilkesiana*: a preliminary study of fungal isolates of clinical significance. *Afr J Infect Dis*. 2021;16(1):21–30. <https://doi.org/10.21010/Ajid.v16i1.4>
232. Jowkar F, Jamshidzadeh A, Pakniyat S, Namazi MR. Efficacy of nitric oxide-liberating cream on pityriasis versicolor. *J Dermatolog Treat*. 2010;21(2):93–96. <https://doi.org/10.3109/09546630902887229>
233. Nashwa RK, Ahmed EB, Nemr WA. Comparative study between topically applied irradiated human amniotic membrane in combination with tea tree oil versus topical tioconazole in pityriasis versicolor treatment. *Cell Tissue Bank*. 2020;21(2):313–320. <https://doi.org/10.1007/s10561-020-09824-5>